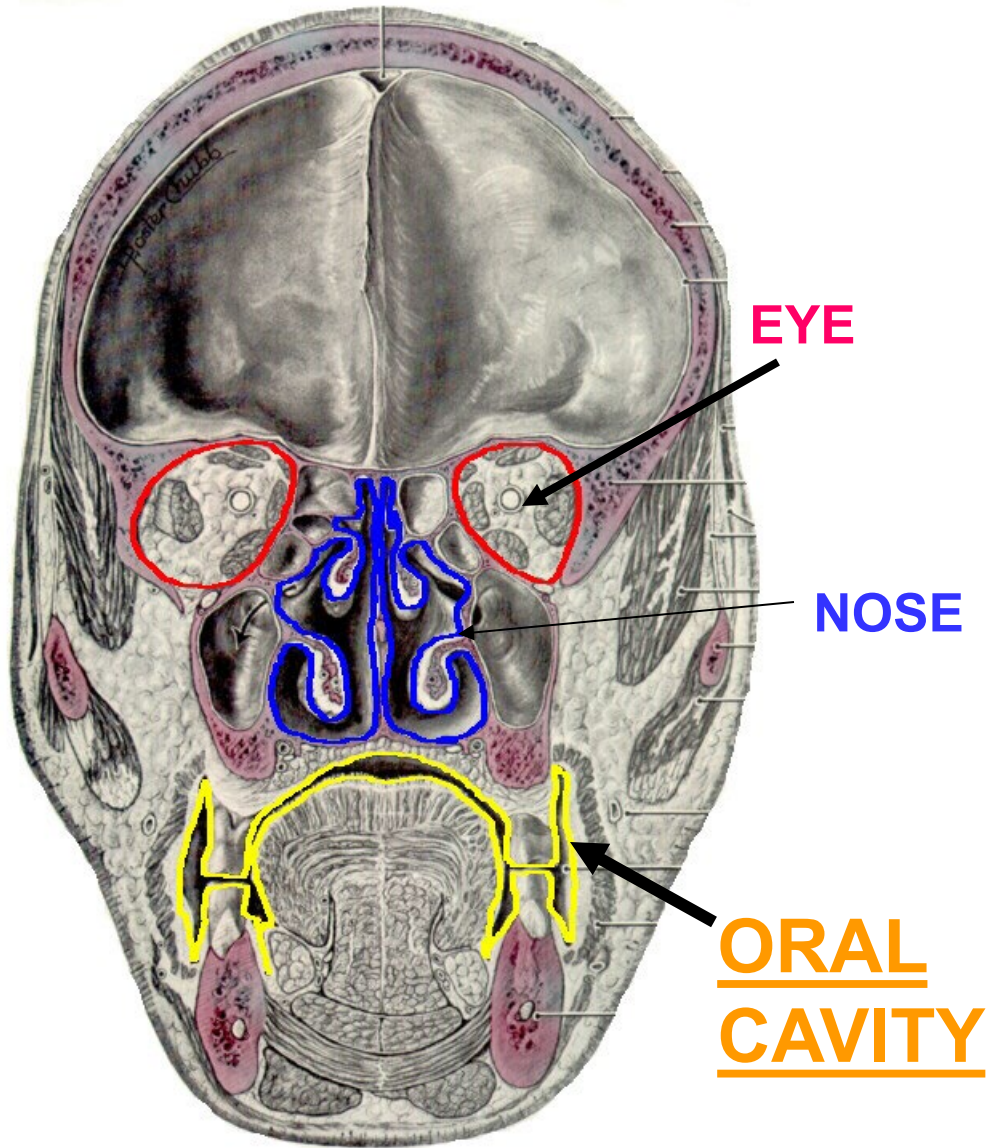


ORAL CAVITY

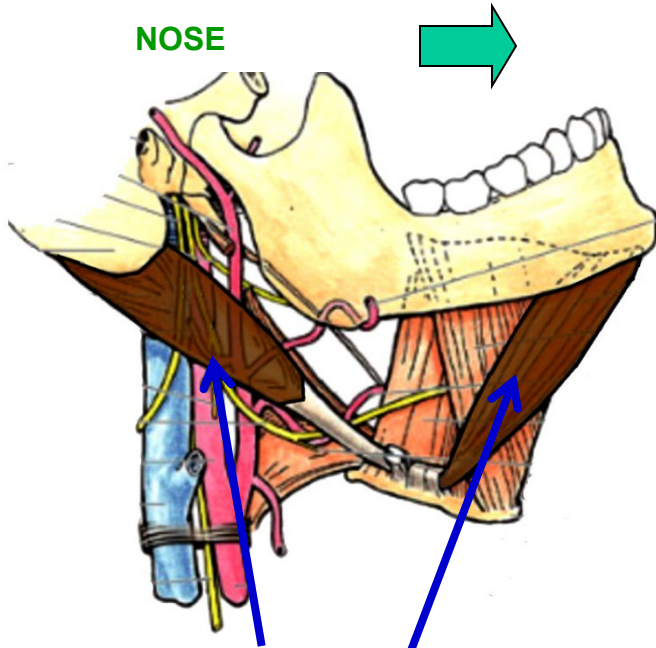


- OUTLINE: ORAL CAVITY**
- I. SUBMANDIBULAR REGION**
 - II. TONGUE**
 - III. NERVES, ARTERIES, SALIVARY GLANDS**

word on the street (of day) - ANGINA = condition with intense pain: from L. or G., strangling, choking

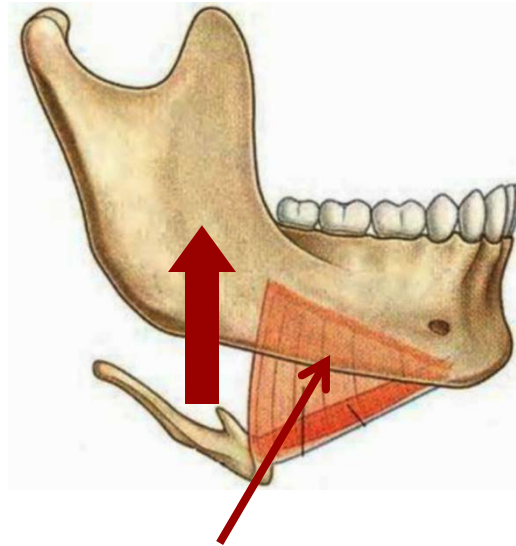
I. SUBMANDIBULAR REGION = AREA BETWEEN MANDIBLE AND HYOID BONE; REVIEW MUSCLES

view from inside mouth



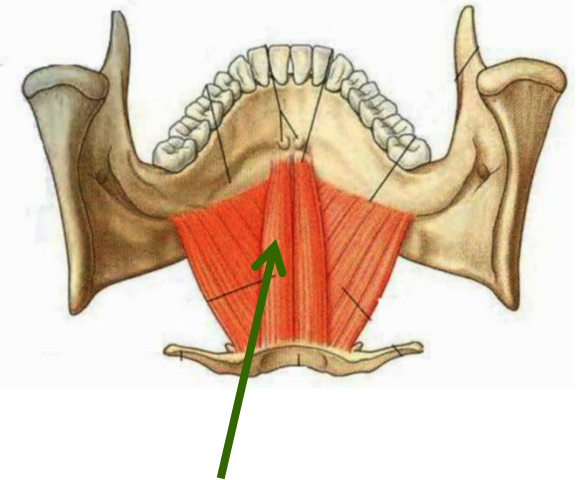
DIGASTRIC

**ACTION - Depress
mandible, OPEN
MOUTH
INN - V3, VII**



MYLOHYOID

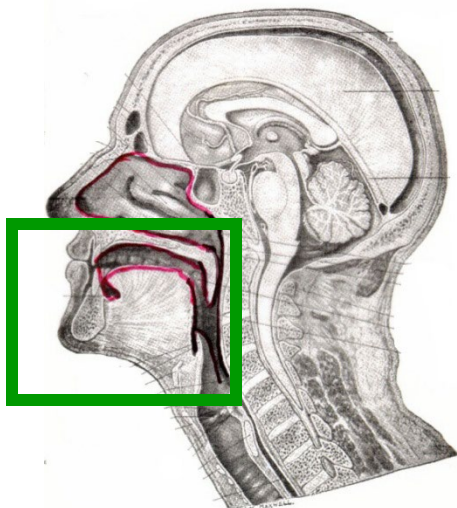
**ACTION - Elevate
hyoid,
RAISE FLOOR OF
MOUTH
INN - V3**



GENIOHYOID

**ACTION - PULL
HYOID FORWARD
INN - C1 (with XII)**

SUBMANDIBULAR REGION *

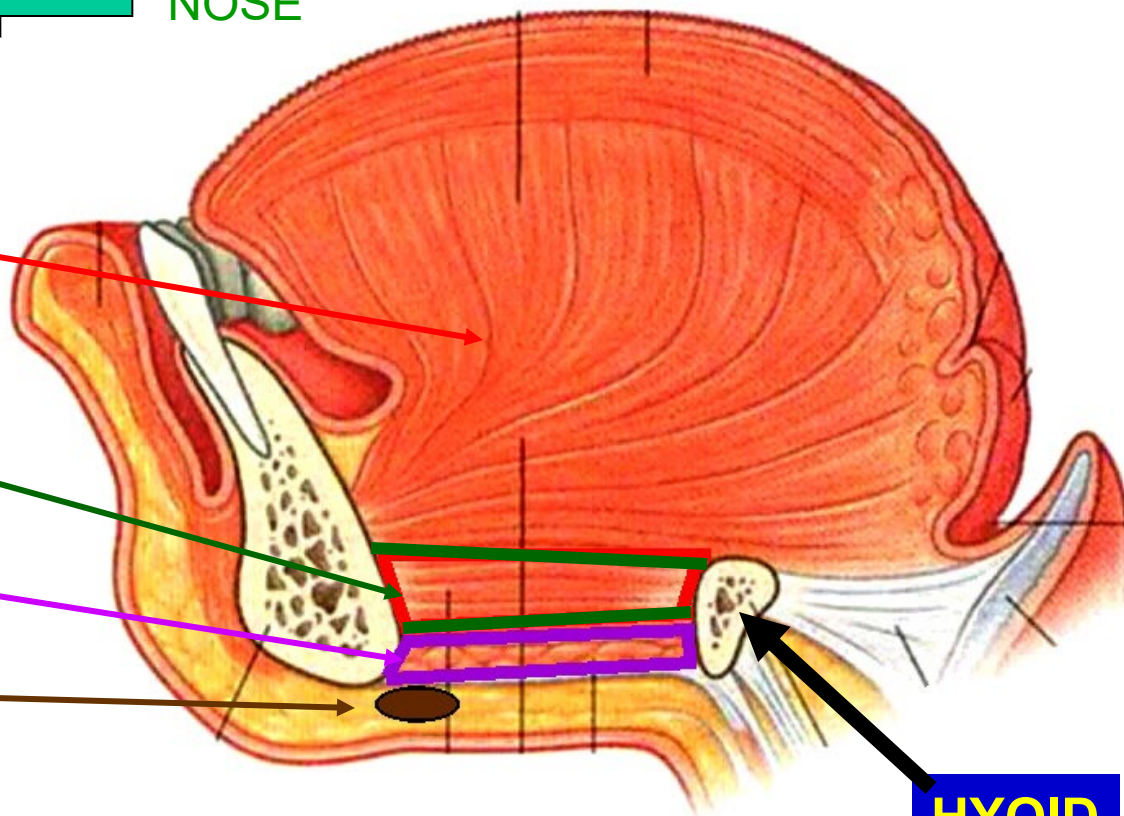


GENIOGLOSSUS
- mandible-tongue

GENIOHYOID
- mandible-hyoid

MYLOHYOID
- cut on end

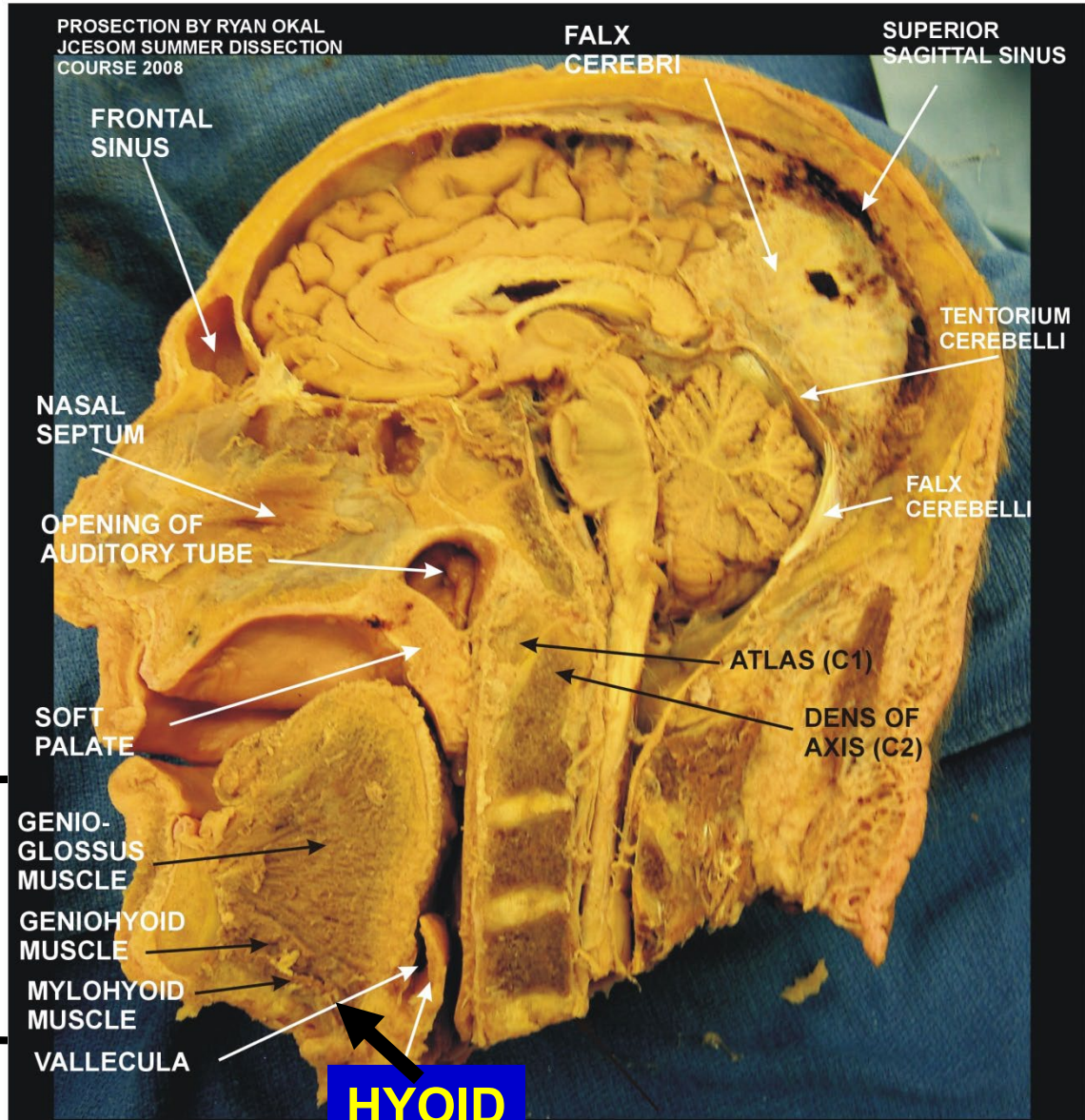
DIGASTRIC



**HYOID
BONE**

**MUSCLES VIEWED ON BISECTED HEAD – ID ON
PRACTICAL BASED ON LOCATION, FIBER ORIENTATION**

PROSECTON BY RYAN OKAL
JCESOM SUMMER DISSECTION
COURSE 2008

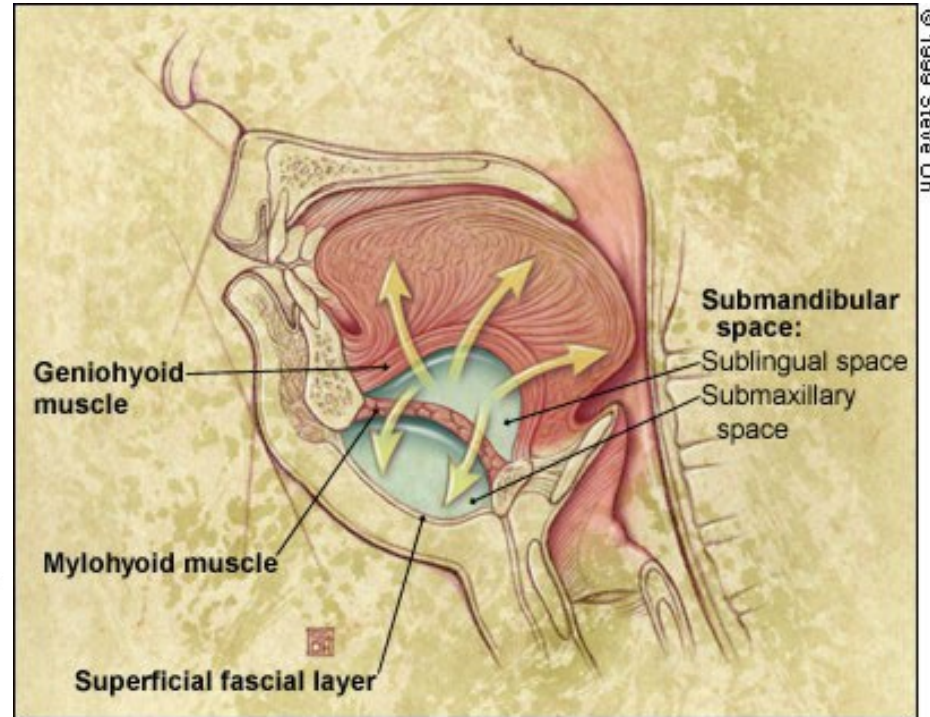
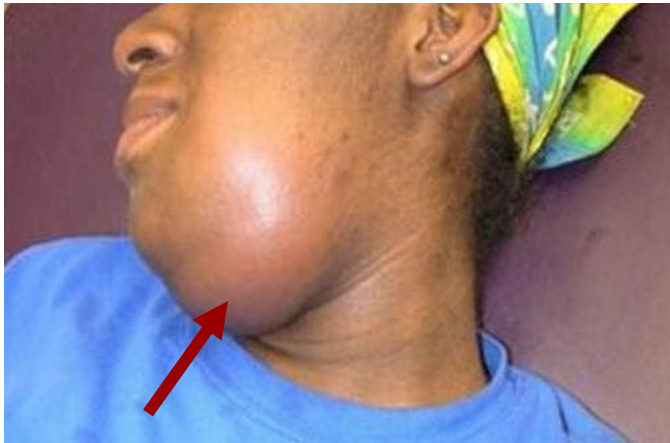

**MUSCLES
OF
FLOOR
OF
MOUTH**

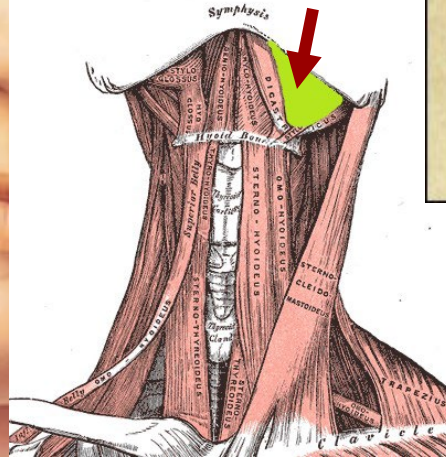
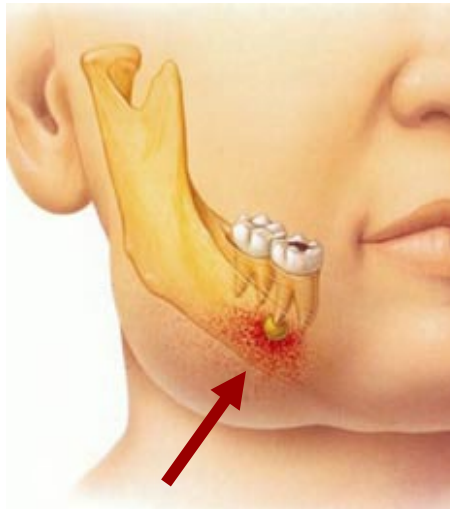**HYOID
BONE**

EP

BOARD QUESTION: LUDWIG'S ANGINA - infection of floor of mouth (Submandibular space), often due to spread from abscessed mandibular tooth *



© 1999 Steve Oh




tooth abscess

**Submandibular Space -
in Anterior Triangle of neck**


**Infection may obstruct
airway, push up tongue**

**Angina = condition with
intense pain: from L.
strangling**


IMPLICIT: EXCELLENCE IN ANATOMY/SCIENCE IS CORRELATED WITH THE PRESENCE OF A MOUSTACHE/BEARD



**WILHELM FREDERICK
VON LUDWIG (1790-
1865) -**
- German surgeon
- first described
submandibular
infection



WALDEYER -
- coined term neuron
- reputation: stealing
ideas from others
- however, identified
all tonsils/lymphatic
tissues in head

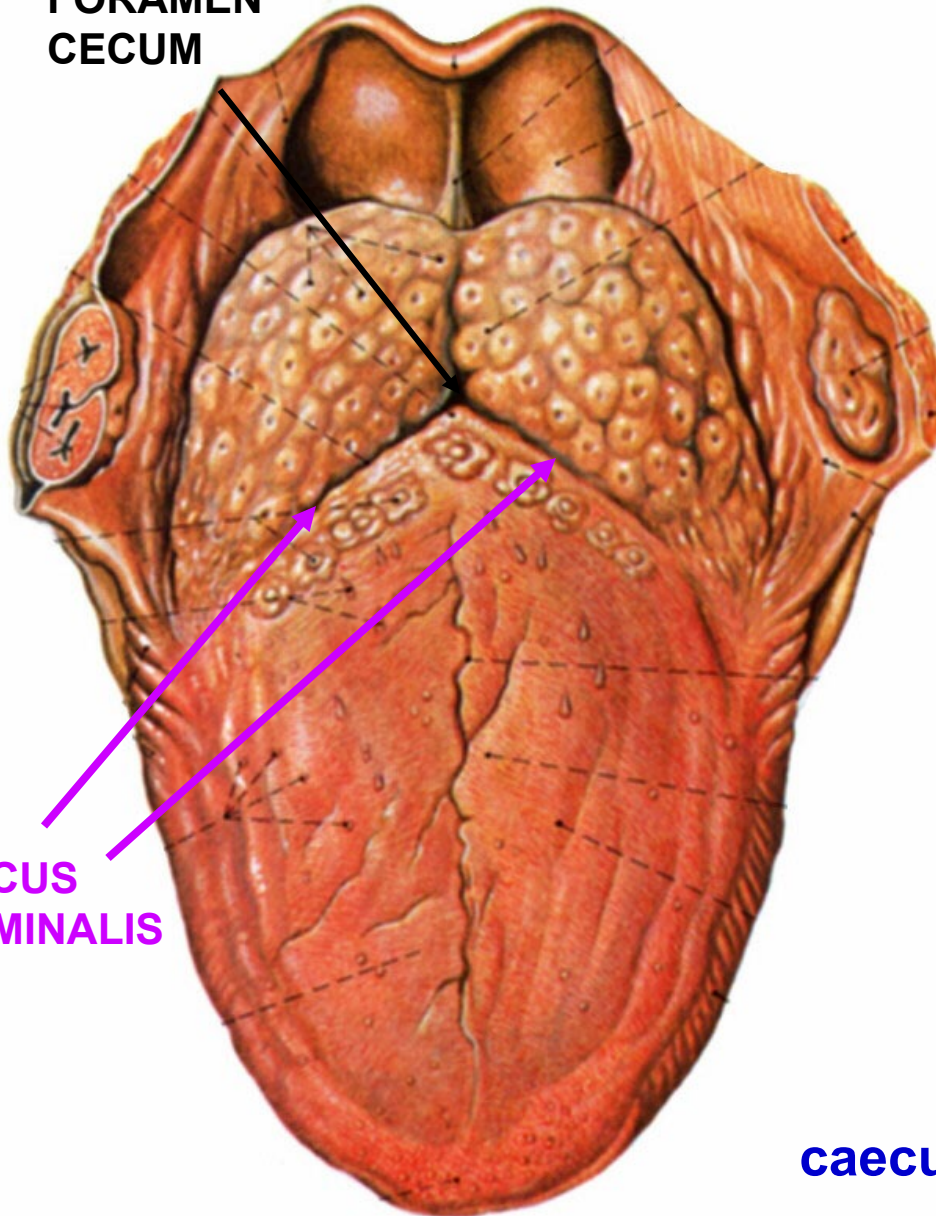


GOLGI -
- reputation: genius
- identified cell
organelles
- identified sense
organs in muscle
tendons

Fact: No clear correlation exists; most early anatomists/scientists were male; most males had facial hair; there are/were also many excellent female scientists (ex. Rosalind Franklin, Jane Macpherson)

II. TONGUE

FORAMEN
CECUM



MOBILE MUSCULAR ORGAN
ATTACHED TO HYOID, MANDIBLE and
SKULL BY MUSCLES

**FUNCTIONS: CHEWING FOOD,
SPEECH, SWALLOWING, TASTE AND
INFANTILE EMOTIONAL
EXPRESSIONS**

A. SUPERFICIAL STRUCTURES

1. SULCUS TERMINALIS - V-SHAPE
GROOVE DIVIDES TONGUE INTO:
ANT. 2/3- ORAL PART - SOMATIC
SENSORY; POST 1/3 -PHARYNGEAL
PART - VISCERAL SENSORY

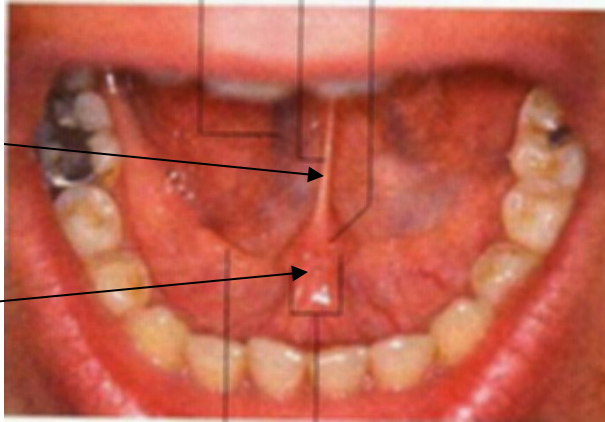
2. FORAMEN CAECUM - PIT IN
MIDDLE OF SULCUS TERMINALIS-
SITE OF INVAGINATION OF THYROID
GLAND

caecum - L. blind pouch

SULCUS
TERMINALIS

LINGUAL FRENULUM

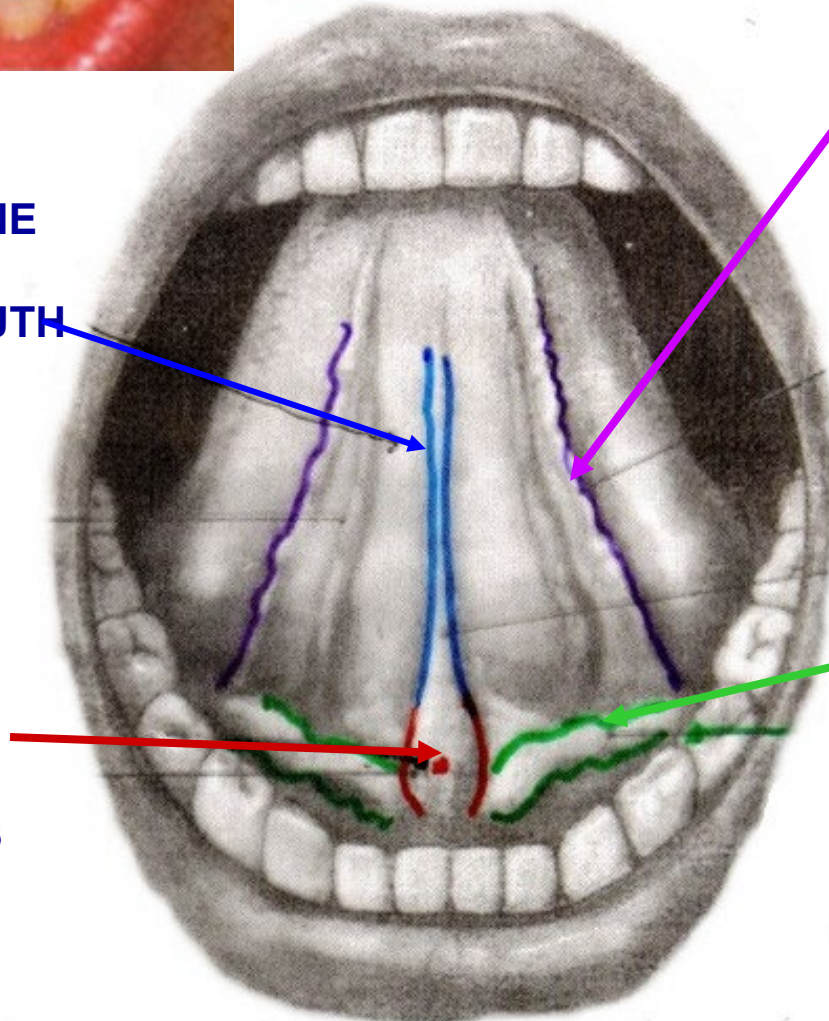
SUB-LINGUAL PAPILLA



FOLDS, LANDMARKS BENEATH TONGUE

3. LINGUAL FRENULUM (L. BRIDLE) MIDLINE FOLD FROM FLOOR OF MOUTH

SUBLINGUAL PAPILLA- SWELLING AT BASE OF FRENULUM; OPENINGS SUBMANDIB. SALIV. GLANDS



4. FIMBRIATED FOLDS (PLICA FIMBRIATA) (L. FRINGE) - LATERAL TO LINGUAL FRENULUM, LOCATION OF LINGUAL VEINS

5. SUBLINGUAL FOLDS (PLICA SUBLINGUALIS) OVERLIE and HAVE OPENINGS FOR SUBLINGUAL SALIV GLANDS

B. MUSCLES OF TONGUE - all innervated by XII

A) GENIOGLOSSUS

- O - GENIAL TUBERCLE OF MANDIBLE
- I - TONGUE TO ITS DORSAL SURFACE
- A - PROTRUDE

1. EXTRINSIC MUSCLES -

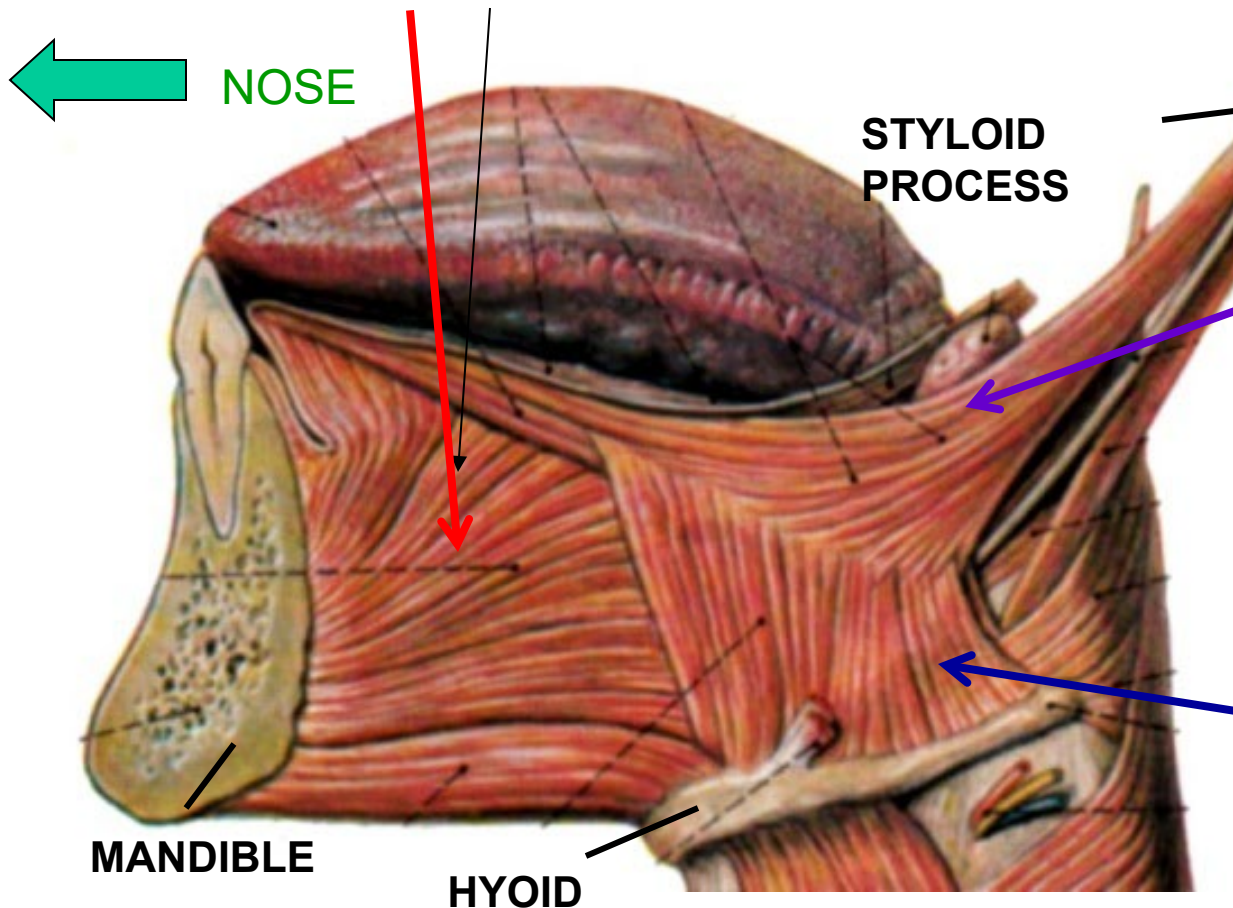
ATTACH TONGUE TO BONES

C) STYLOGLOSSUS -

- O - STYLOID PROCESS OF TEMP. BONE
- I - LAT. SIDE OF TONGUE
- A - DRAWS TONGUE SUPERIORLY and POSTERIORLY

B) HYOGLOSSUS -

- O - GREATER & LESSER HORNS OF HYOID BONE
- I - LAT. SIDE OF TONGUE
- A - DEPRESS

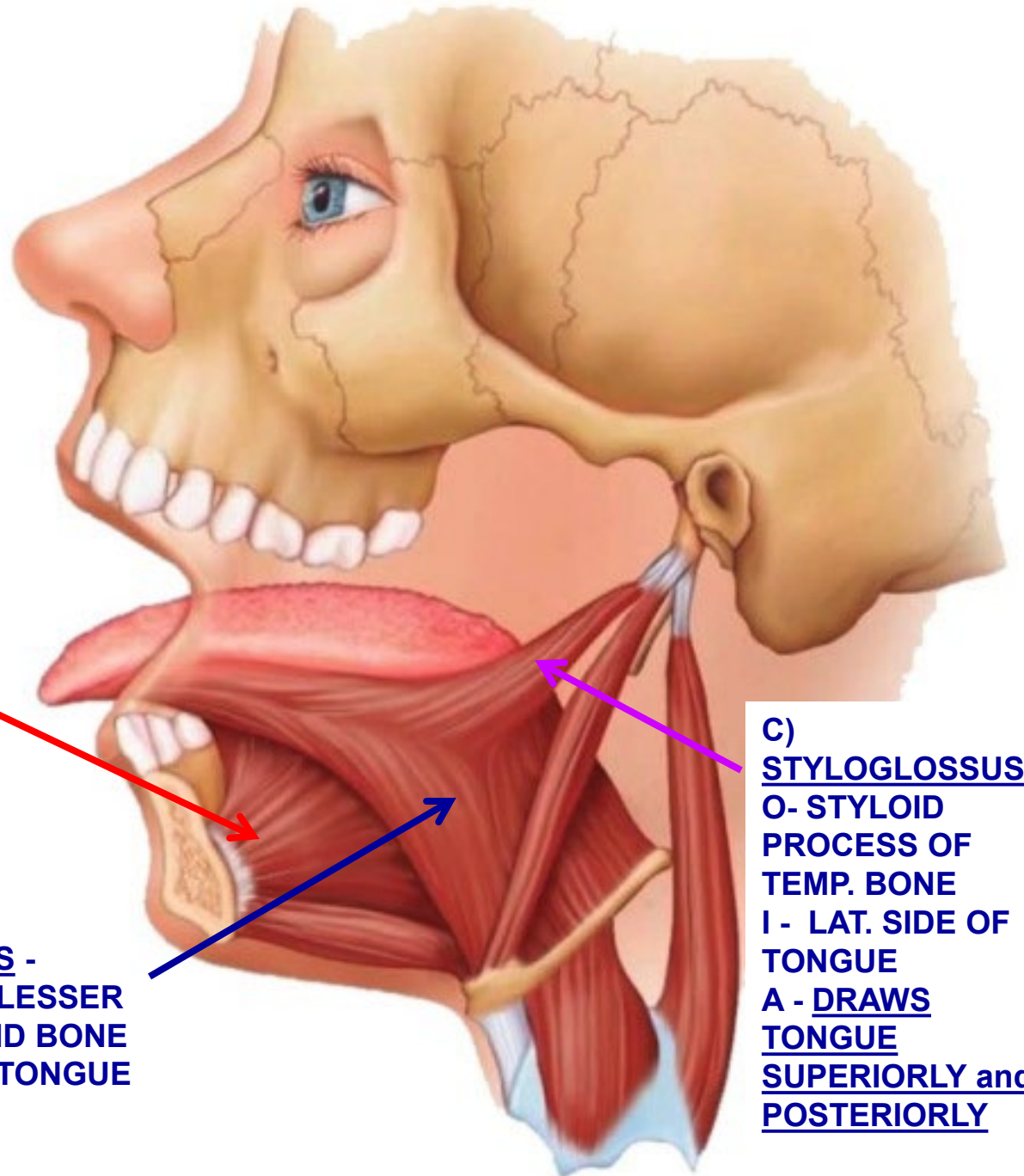


B. MUSCLES OF TONGUE - all innervated by XII

A) GENIOGLOSSUS
O - GENIAL TUBERCLE OF MANDIBLE
I - TONGUE TO ITS DORSAL SURFACE
A - PROTRUDE

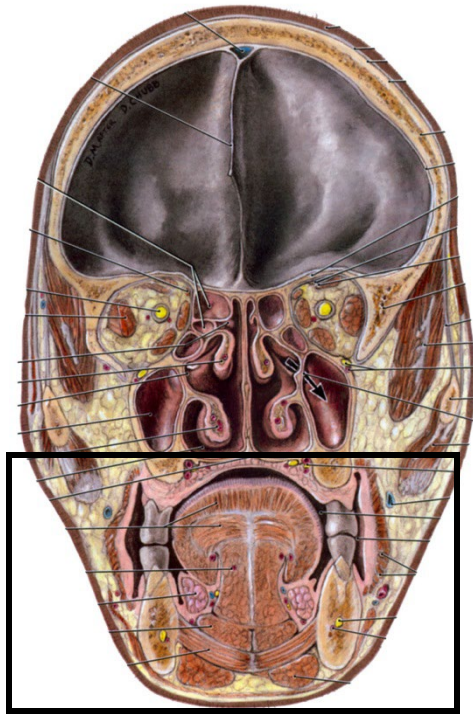
B) HYOGLOSSUS -
O - GREATER & LESSER HORNS OF HYOID BONE
I - LAT. SIDE OF TONGUE
A - DEPRESS

C) STYLOGLOSSUS -
O - STYLOID PROCESS OF TEMP. BONE
I - LAT. SIDE OF TONGUE
A - DRAWS TONGUE SUPERIORLY and POSTERIORLY



2. INTRINSIC MUSCLES OF TONGUE

A) VERTICAL M. - FIBERS SUP & INF - FLATTEN and BROADEN TONGUE

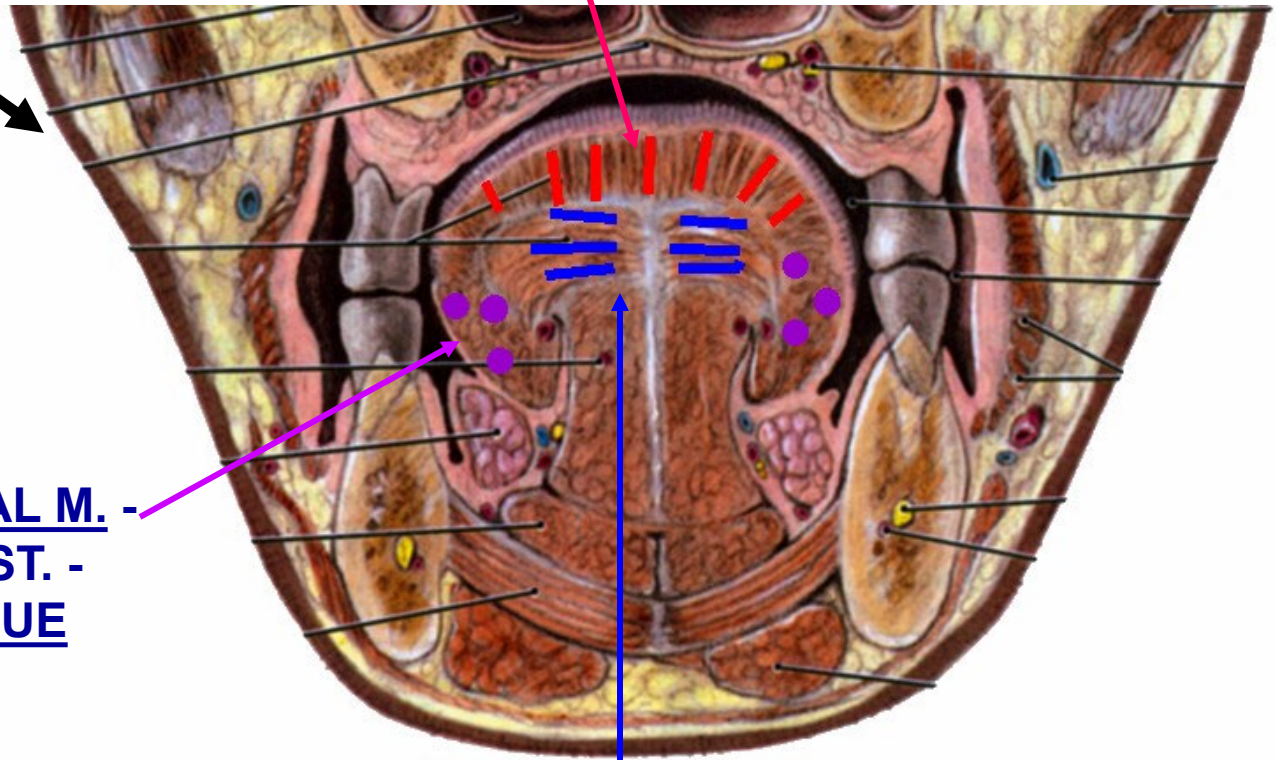


CORONAL SECTION

C) LONGITUDINAL M. - FIBERS ANT-POST. - SHORTEN TONGUE

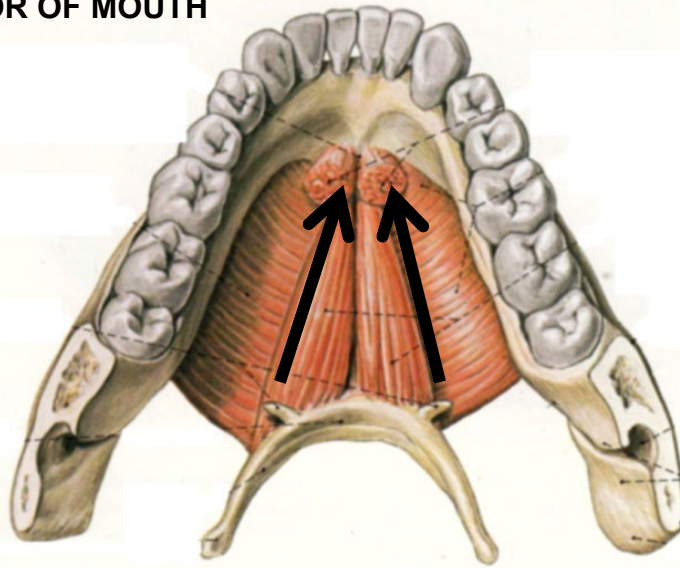
ALL INTRINSIC AND
EXTRINSIC MUSCLES –
INN BY CN XII

B) TRANSVERSE M. - FIBERS HORIZONTAL -
NARROW TONGUE



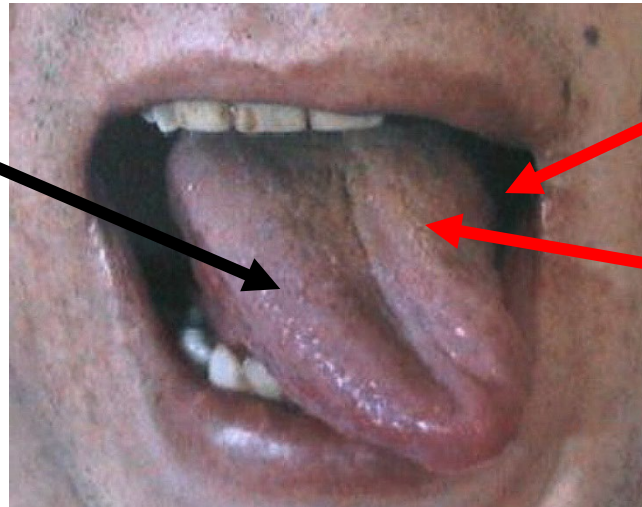VIEW OF FLOOR OF MOUTH

**GENIO-
GLOSSUS
DIRECTION
OF
ACTION**



**CLINICAL SIGN OF
DAMAGE TO
HYPOGLOSSAL
NERVE (XII)**

**GENIO-
GLOSSUS
INTACT**



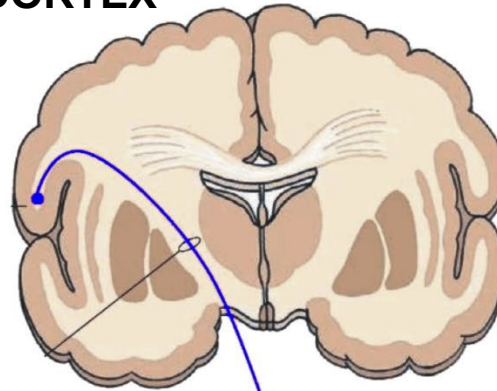
**DAMAGE
HYPOGLOSSAL
NERVE ON ONE
SIDE**

**GENIO-
GLOSSUS
PARALYZED**

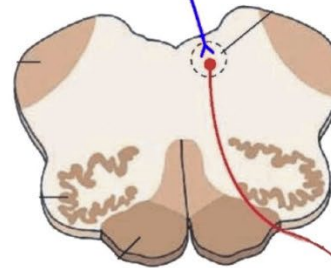
**LOWER MOTOR NEURON LESION - PROTRUDED TONGUE **
DEVIATES TOWARD SIDE OF LESION - due to unopposed action
of the **Genioglossus** muscle.**

UPPER MOTOR NEURON TO GENIOGLOSSUS - CONTRALATERAL

CORTEX



BRAINSTEM - MEDULLA

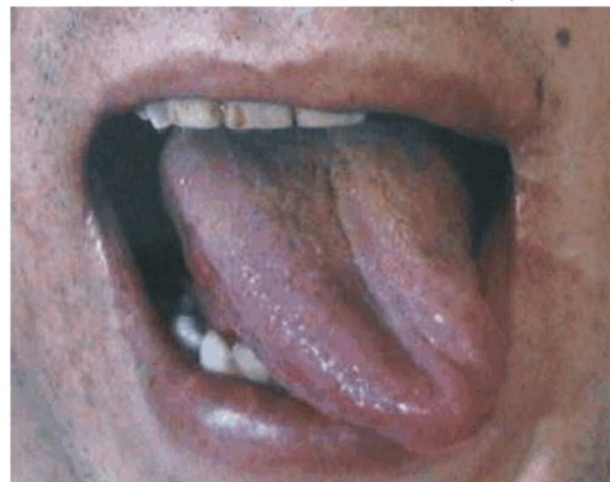

UPPER MOTOR NEURON - CRANIAL NERVES - ALL BILATERAL EXCEPT:

- 1) ONLY CONTRALATERAL:**
 - VII - LOWER FACE (BELOW ORBICULARIS OCULI)
 - XII - GENIOGLOSSUS
 - XI - TRAPEZIUS
- 2) ONLY IPSILATERAL:**
 - XI - STERNOCLEIDOMASTOID

HYPOGLOSSAL LOWER MOTOR TO GENIOGLOSSUS MUSCLE (IPSILATERAL)

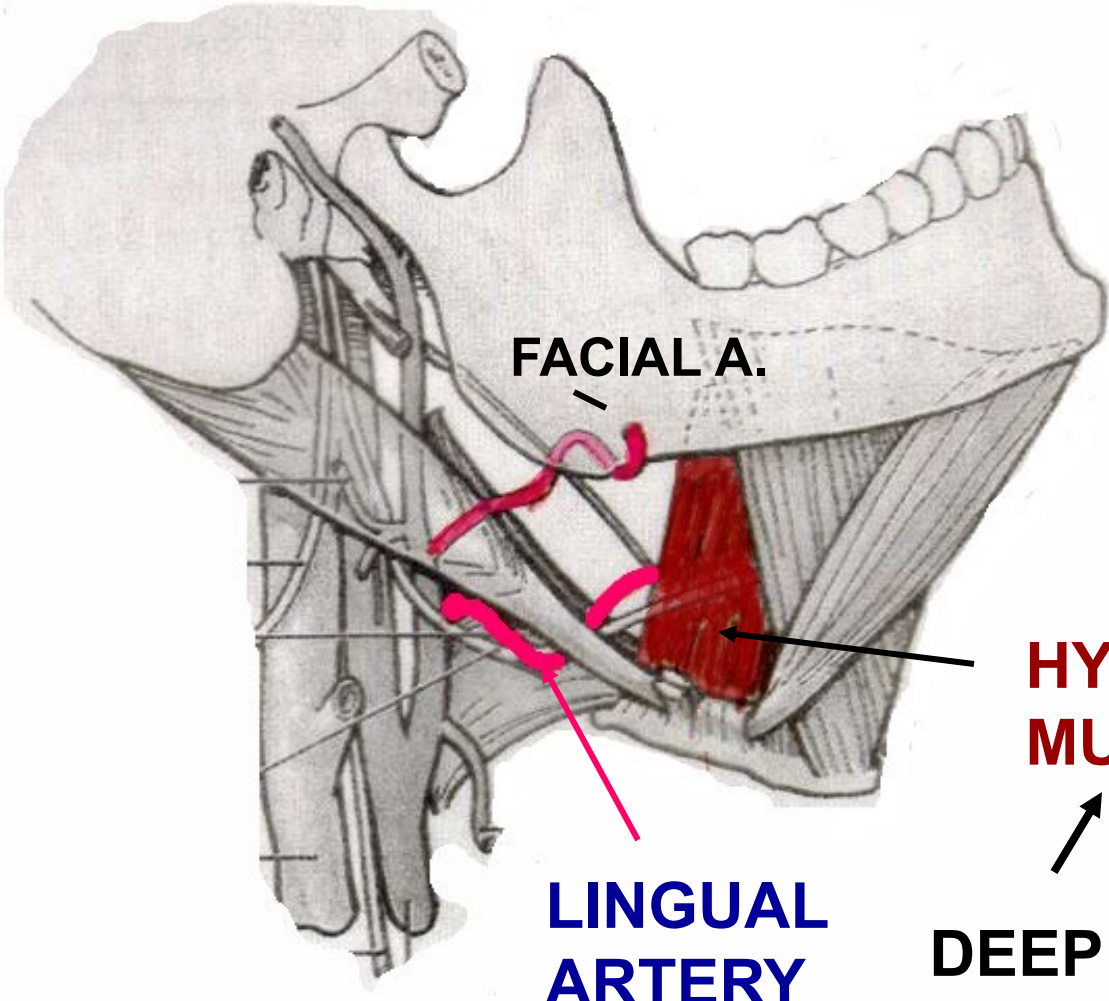
DAMAGE UPPER MOTOR - TONGUE DEVIATES AWAY FROM SIDE OF CORTICAL LESION **



DAMAGE LOWER MOTOR - TONGUE DEVIATES ** TOWARD SIDE OF LOWER MOTOR NEURON LESION

C. ARTERIES TO TONGUE - LINGUAL ARTERY

NOSE →



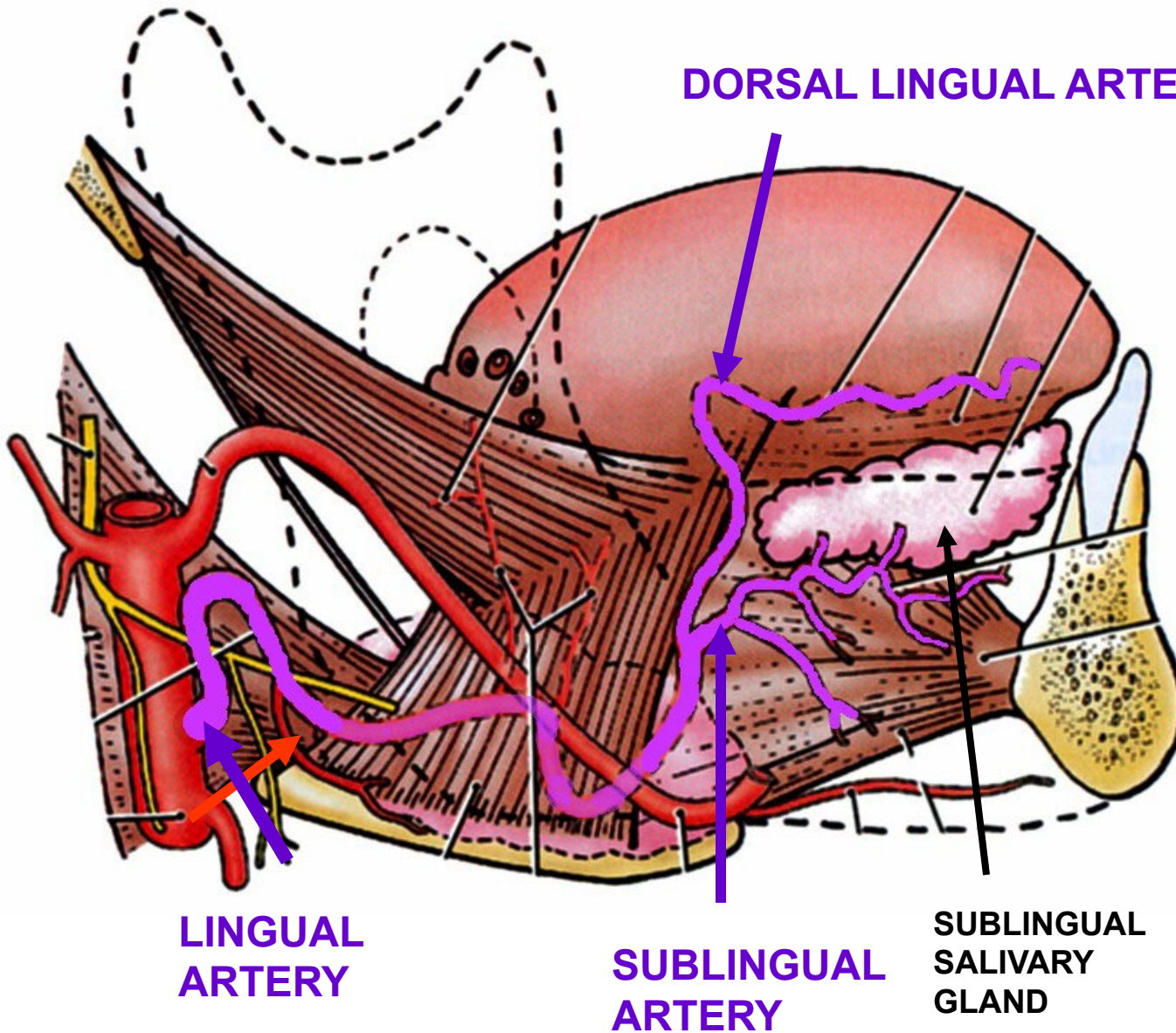
ARISES FROM
EXTERNAL
CAROTID ARTERY
DEEP TO POST
MARGIN OF
HYOGLOSSUS

**HYOGLOSSUS
MUSCLE**

DEEP TO

LINGUAL ARTERY

NOSE →



DORSAL LINGUAL ARTERY

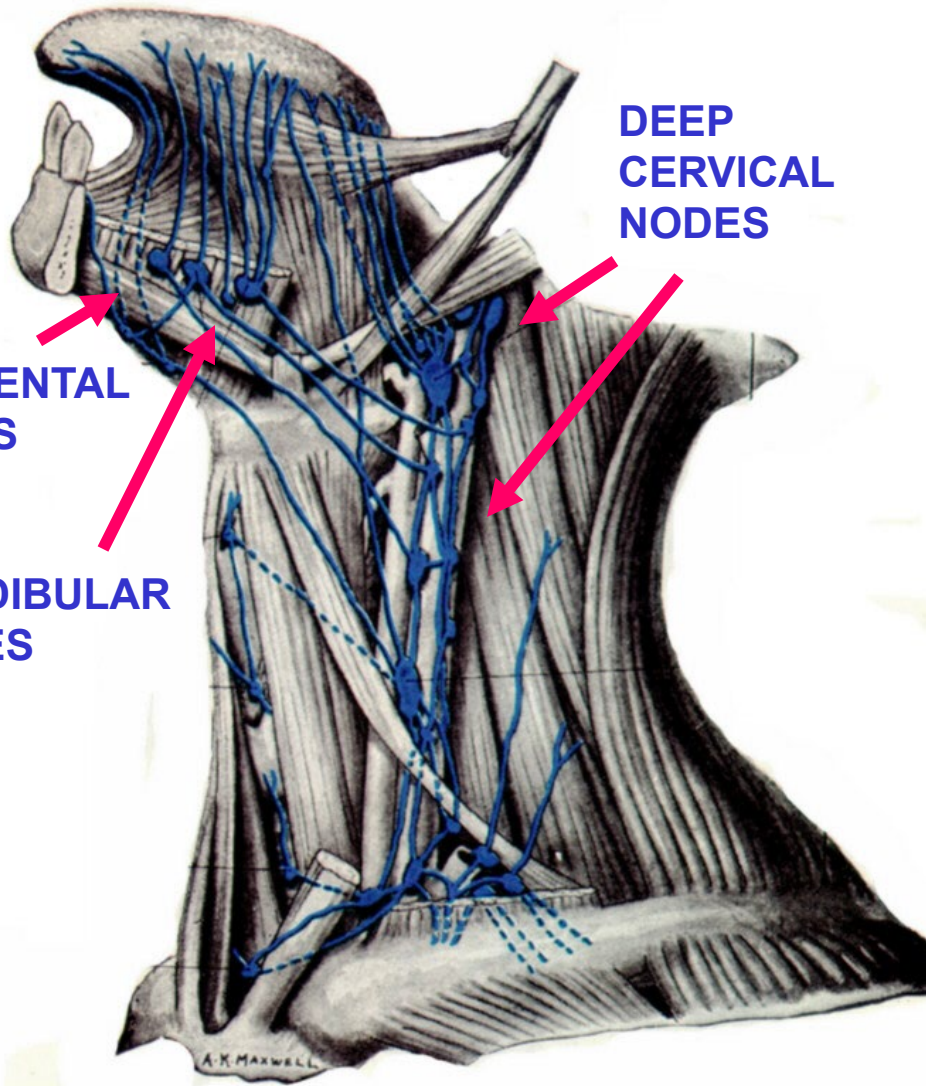
LINGUAL ARTERY- TURNS UPWARD TO SUPPLY TONGUE BRANCHES
A) DORSAL LINGUAL BRANCHES- TO DORSUM OF TONGUE
B) SUBLINGUAL ARTERY - TO SUBLINGUAL SALIVARY GLAND

LINGUAL ARTERY

SUBLINGUAL ARTERY

SUBLINGUAL SALIVARY GLAND

D. LYMPHATICS OF TONGUE



1. TIP OF TONGUE to SUBMENTAL NODES
2. REST OF ANTERIOR 2/3 OF TONGUE to SUBMANDIBULAR NODES AND DEEP CERVICAL LYMPH NODES
3. POSTERIOR 1/3 OF TONGUE TO DEEP CERVICAL LYMPH NODES

NOTE: LYMPH * VESSELS OF TONGUE CROSS MIDLINE; LESION MAY SPREAD TO OPPOSITE SIDE

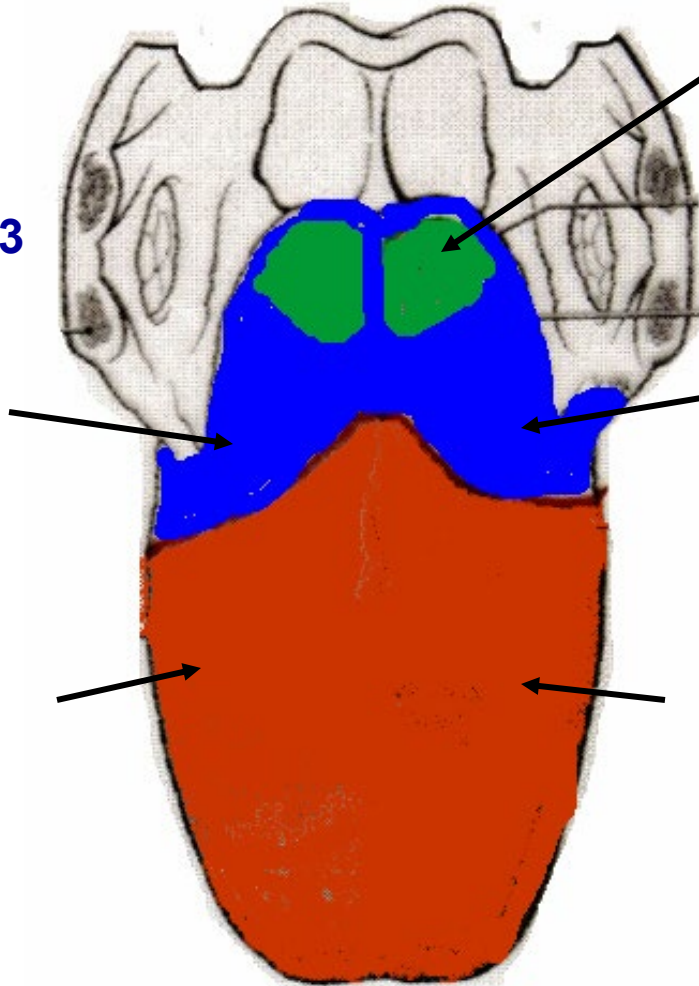
E. SENSORY INNERVATION OF TONGUE

NOTE:



PHARYNGEAL PART- POST 1/3
and ANT. TO
EPIGLOTTIS-
VISCERAL
SENSORY,
TOUCH, PAIN;
TASTE

ORAL PART -
ANT 2/3 -
SOMATIC
SENSORY
TOUCH, PAIN;
TASTE

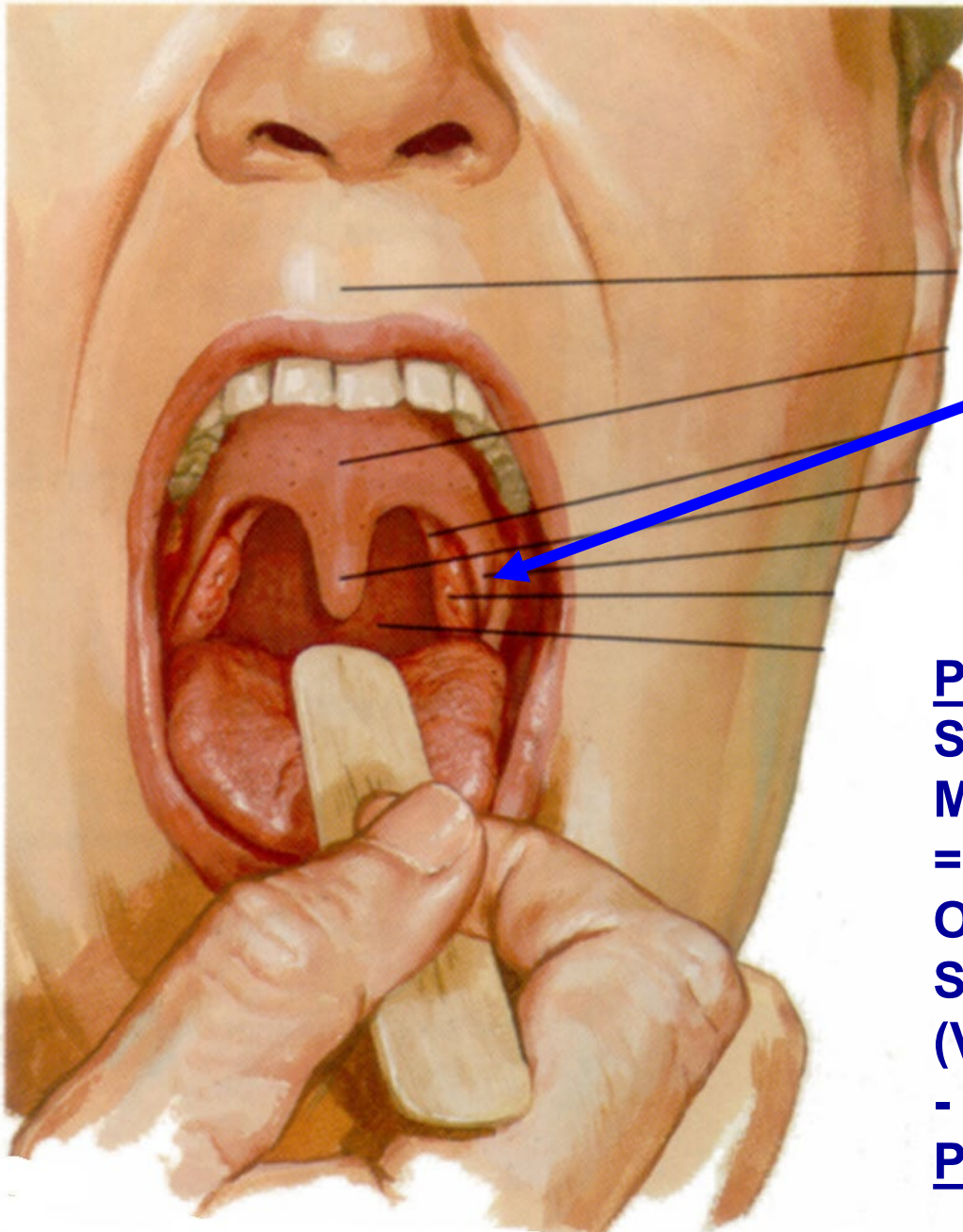


ANT. TO EPIGLOTTIS -
1) X- VAGUS- VISCERAL
SENSORY TOUCH AND
TASTE

POST. 1/3 OF TONGUE
1) IX - GLOSSOPHARYNGEAL
- VISCERAL SENSORY
TOUCH AND TASTE

ANT. 2/3 OF TONGUE
1) V3 - LINGUAL N.
SOMATIC SENSORY TOUCH
2) VII - CHORDA TYMPANI -
TASTE

NOTE: ALL MUSCLES INNERVATED BY XII HYPOGLOSSAL (SOMATIC MOTOR)
NOTE; PALATOGLOSSUS IS MUSCLE OF PALATE INNERVATED BY X (VAGUS)



**SAY
AAHH!**

**PALATOGLOSSAL
ARCH**

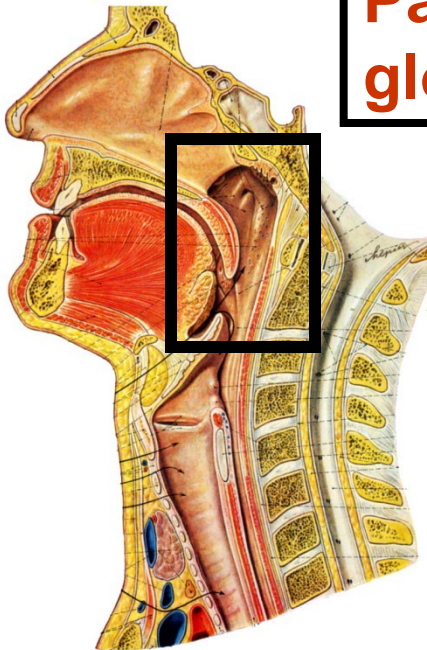
**PALATOGLOSSAL ARCH =
SITE OF OROPHARYNGEAL
MEMBRANE
= BOUNDARY BETWEEN
ORAL CAVITY (SOMATIC
SENSORY) AND PHARYNX
(VISCERAL SENSORY)
- OVERLIES
PALATOGLOSSUS MUSCLE**

PALATOGLOSSUS IS A MUSCLE OF SOFT PALATE

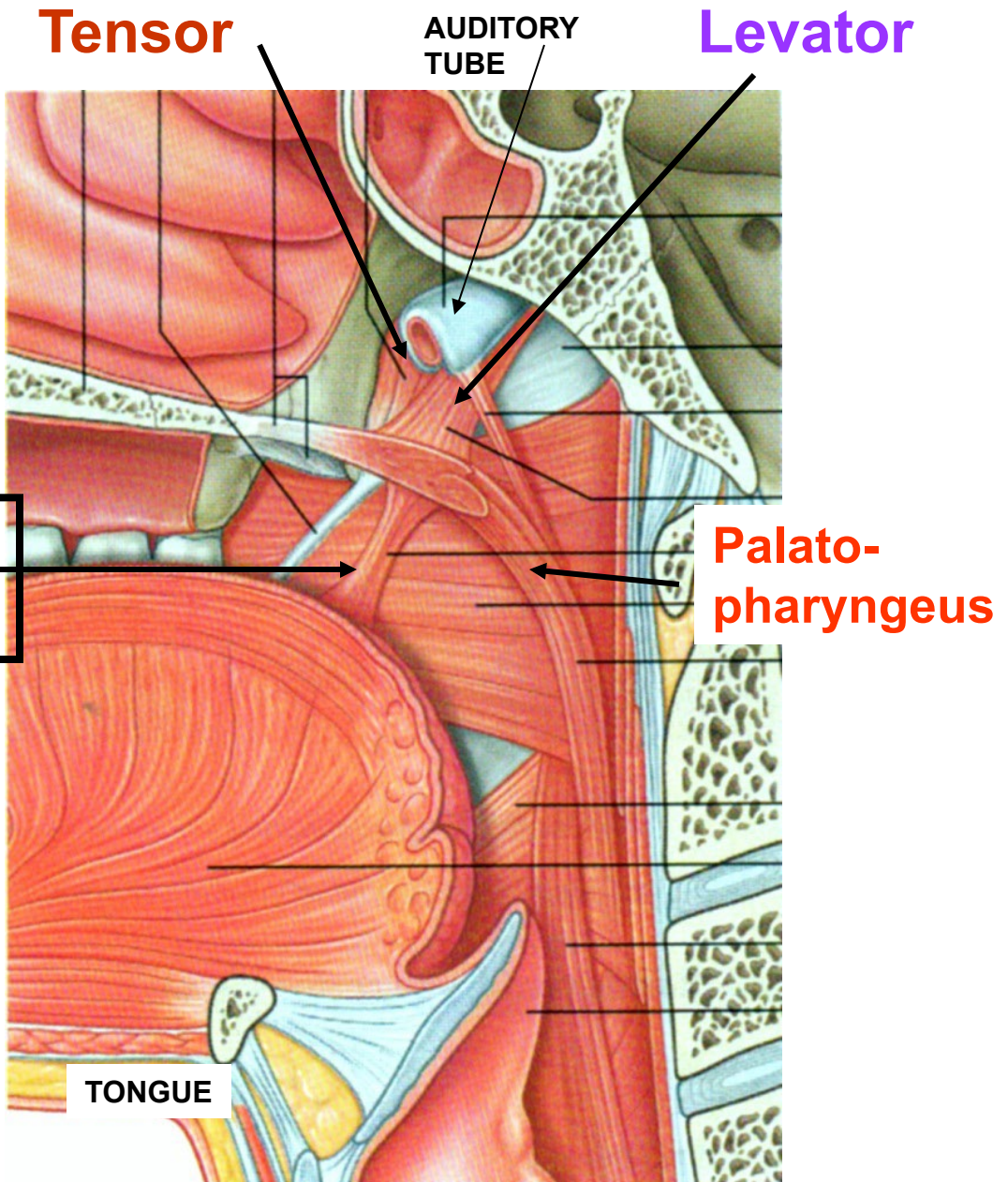
Innervation - VAGUS
CN X

Palatoglossus

O - Palatine
aponeurosis, I - Side of
tongue; A - Draws
palate down, raises
tongue



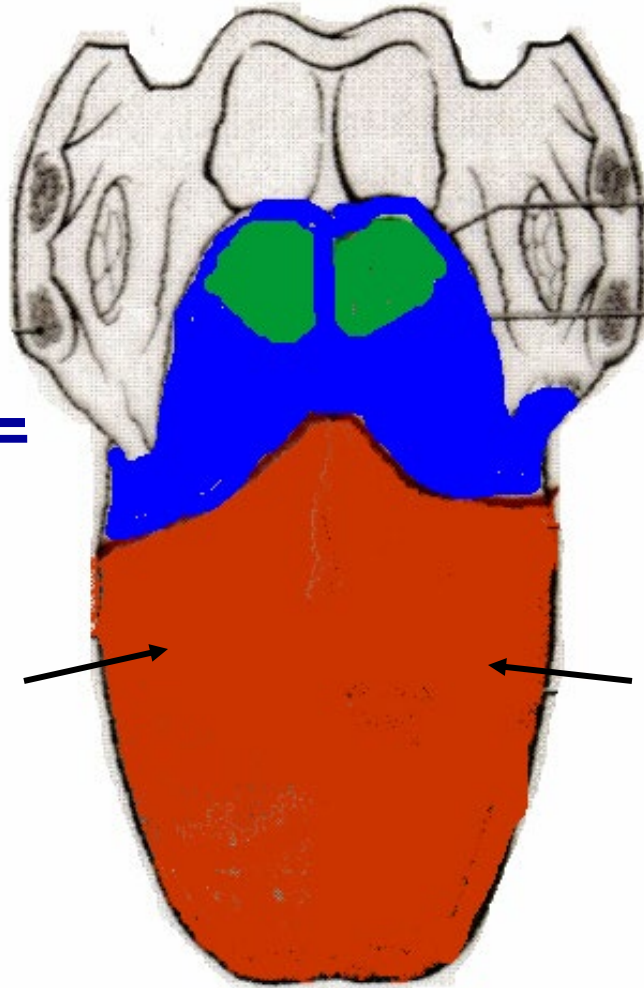
**Palato-
glossus**



III. INNERVATION OF ANTERIOR 2/3 OF TONGUE - in two Cranial Nerves - V, VII

SOMATIC SENSORY -
(GSA)
IN TRIGEMINAL N. (V)

V3 - LINGUAL N. -
SOMATIC SENSORY TOUCH

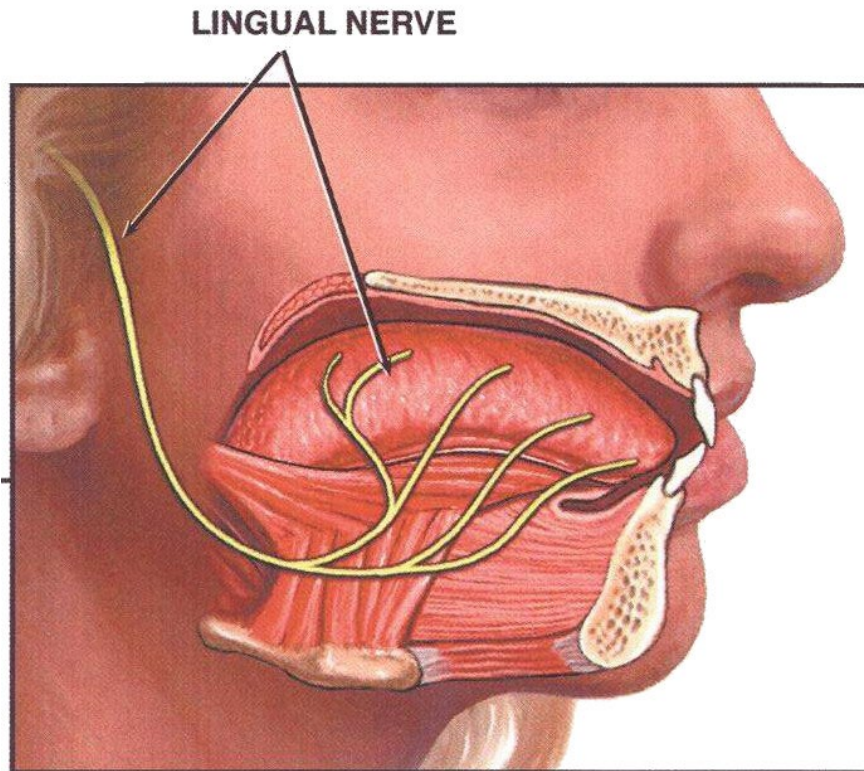


TASTE -
(SVA)
IN FACIAL N. (VII)

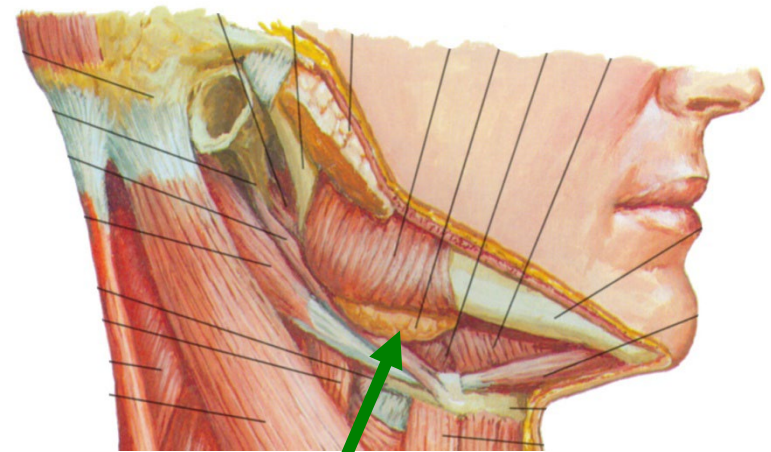
VII - CHORDA TYMPANI -
TASTE

III. PATHWAYS OF NERVES TO TONGUE

LINGUAL NERVE (V3) - PROVIDES SOMATIC SENSATION (precise touch, etc.) to ANT. 2/3 OF TONGUE



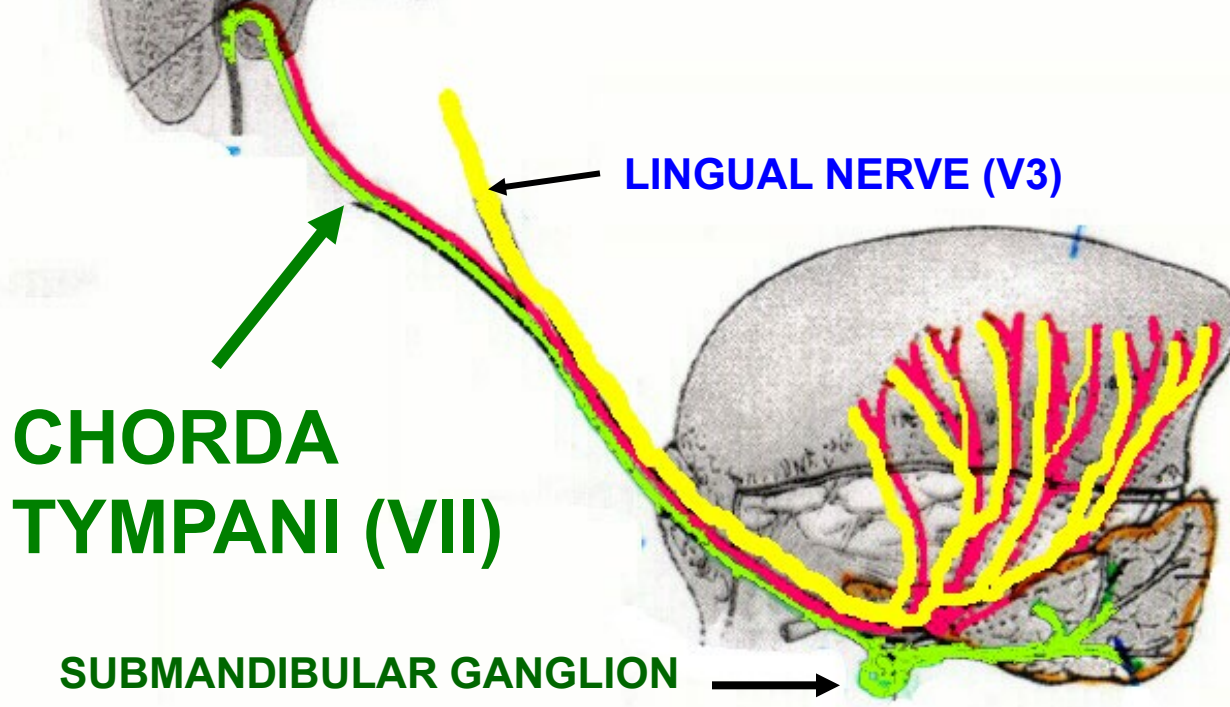
LATERAL VIEW OF THE TONGUE



SUBMANDIBULAR SALIVARY GLAND

LINGUAL NERVE COURSES NEAR SUBMANDIBULAR AND SUBLINGUAL SALIVARY GLANDS

VII CHORDA TYMPANI HITCHHIKES WITH V3 LINGUAL NERVE



CHORDA TYMPANI (VII)

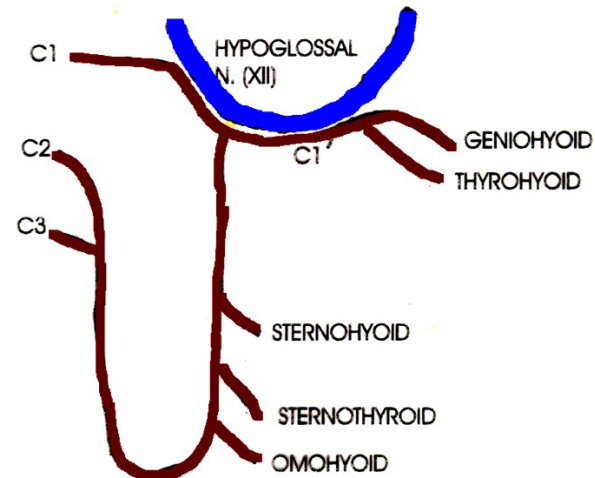
LINGUAL NERVE (V3)

SUBMANDIBULAR GANGLION

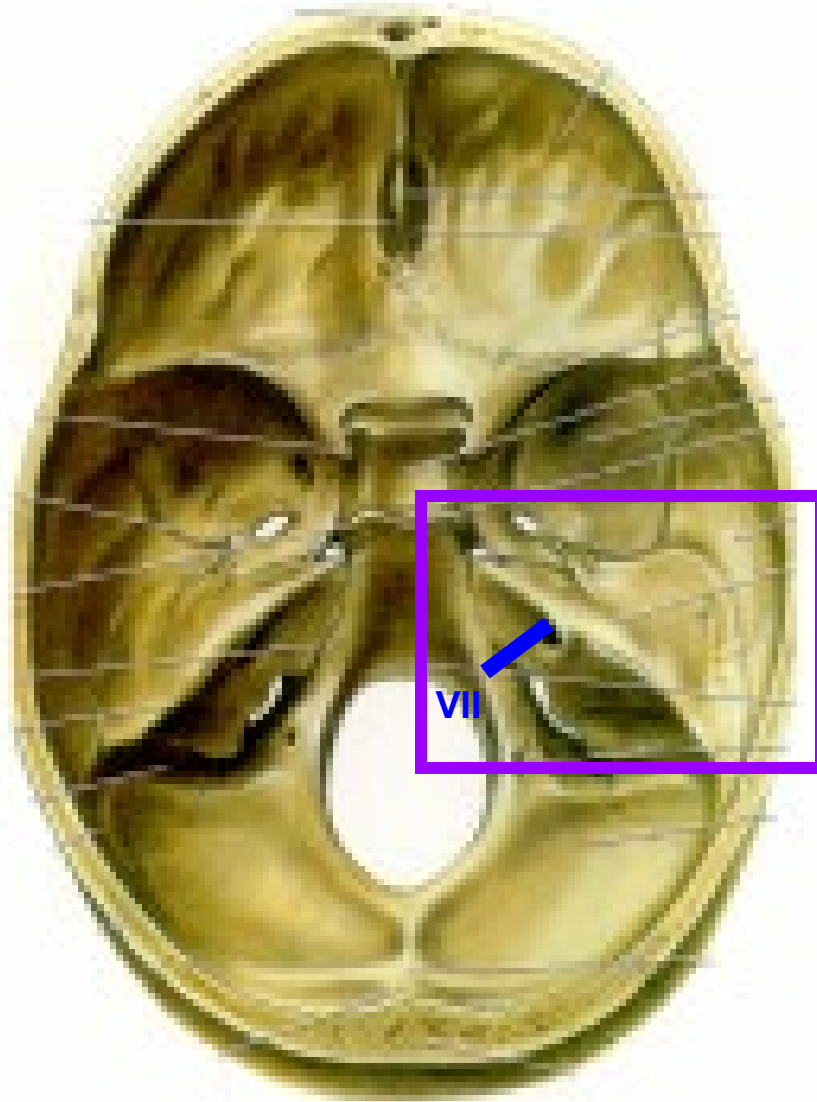
CHORDA TYMPANI (VII)- Parasympathetics - to Submandibular, Sublingual salivary glands - Taste fibers - to taste buds on Ant. 2/3 of tongue

SIMILAR TO ANSA CERVICALIS

RECALL: CN XII Receives hitchhiking fibers of C1



VII – FACIAL – review pathway



**VII leaves Posterior
Cranial fossa via
Internal Auditory
Meatus**

**Look
inside
Petrous
part of
temporal
bone**

FACIAL NERVE

VII leaves Post. Cranial fossa via Internal Aud. Meatus - enters Facial Canal

Branches in Facial Canal

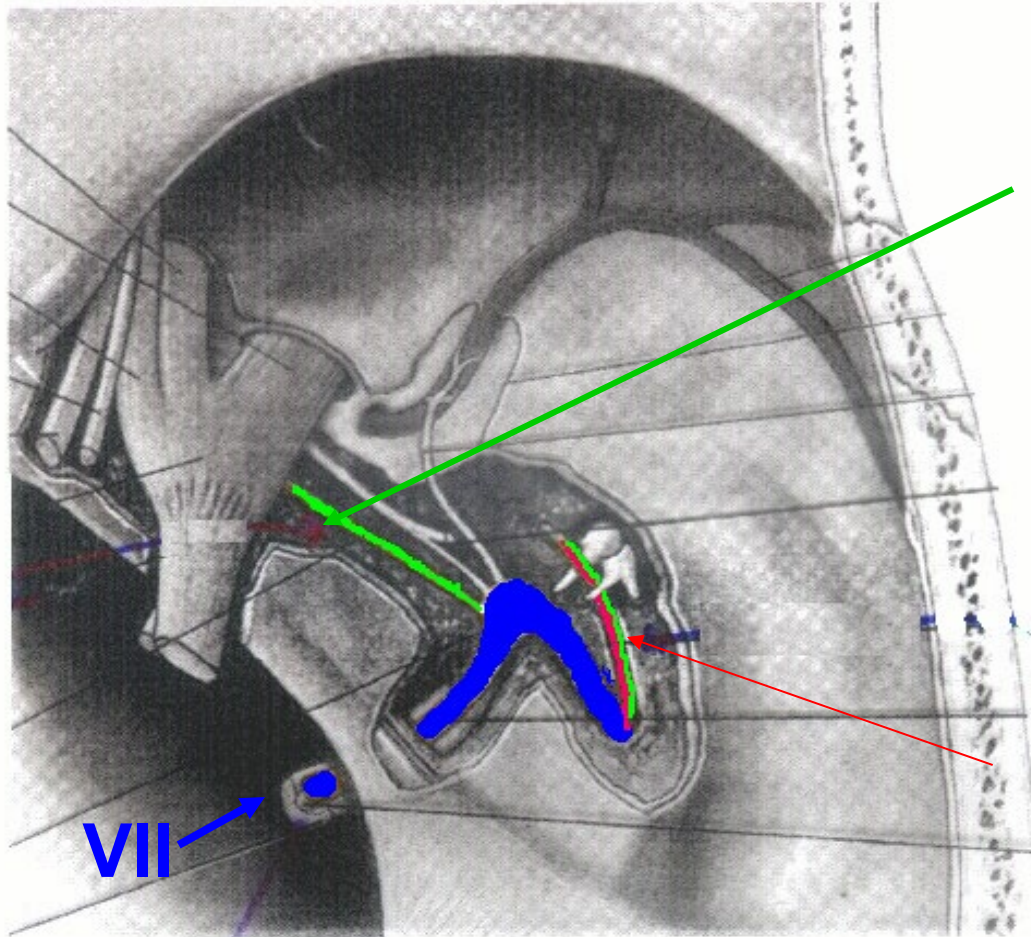
1. Greater Petrosal N.

- Visceral motor Parasymp. to
Lacrimal gland, mucous glands of nose and palate,
- Visceral sensory to Nasopharynx

2. Stapedial N. - Branchio-motor to stapedius

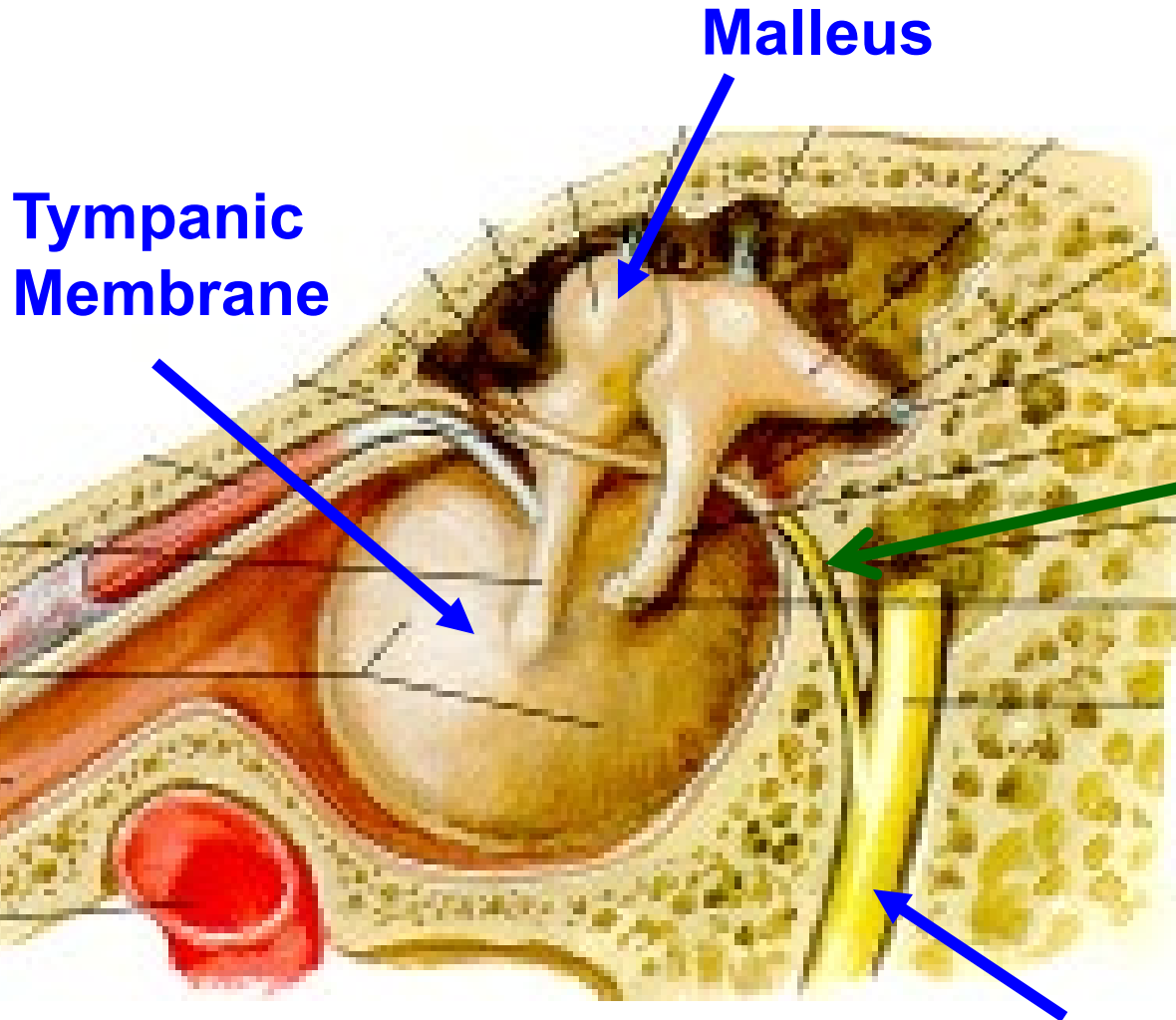
3. Chorda Tympani

Taste to ant 2/3 tongue
Visceral motor Parasymp to submandibular, subling. salivary glands



CHORDA TYMPANI CROSSES TYMPANIC MEMBRANE

Taste to ant. 2/3 of tongue
Parasympathetic to submandibular, sublingual salivary glands



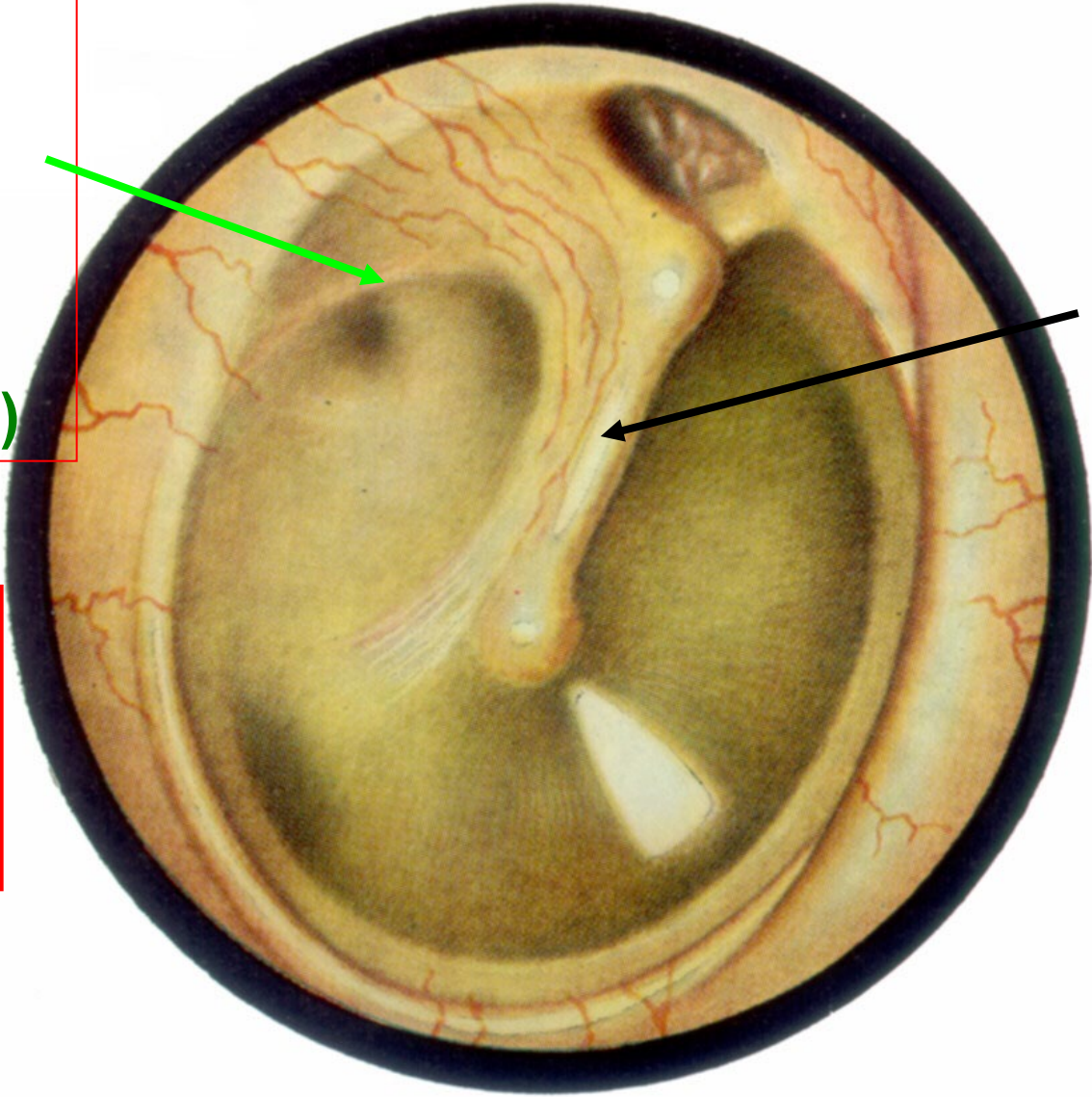
- Chorda Tympani has no function in middle ear
- Crosses through tympanic cavity
- Over handle of malleus

VIEW OF INNER SURFACE

FACIAL NERVE

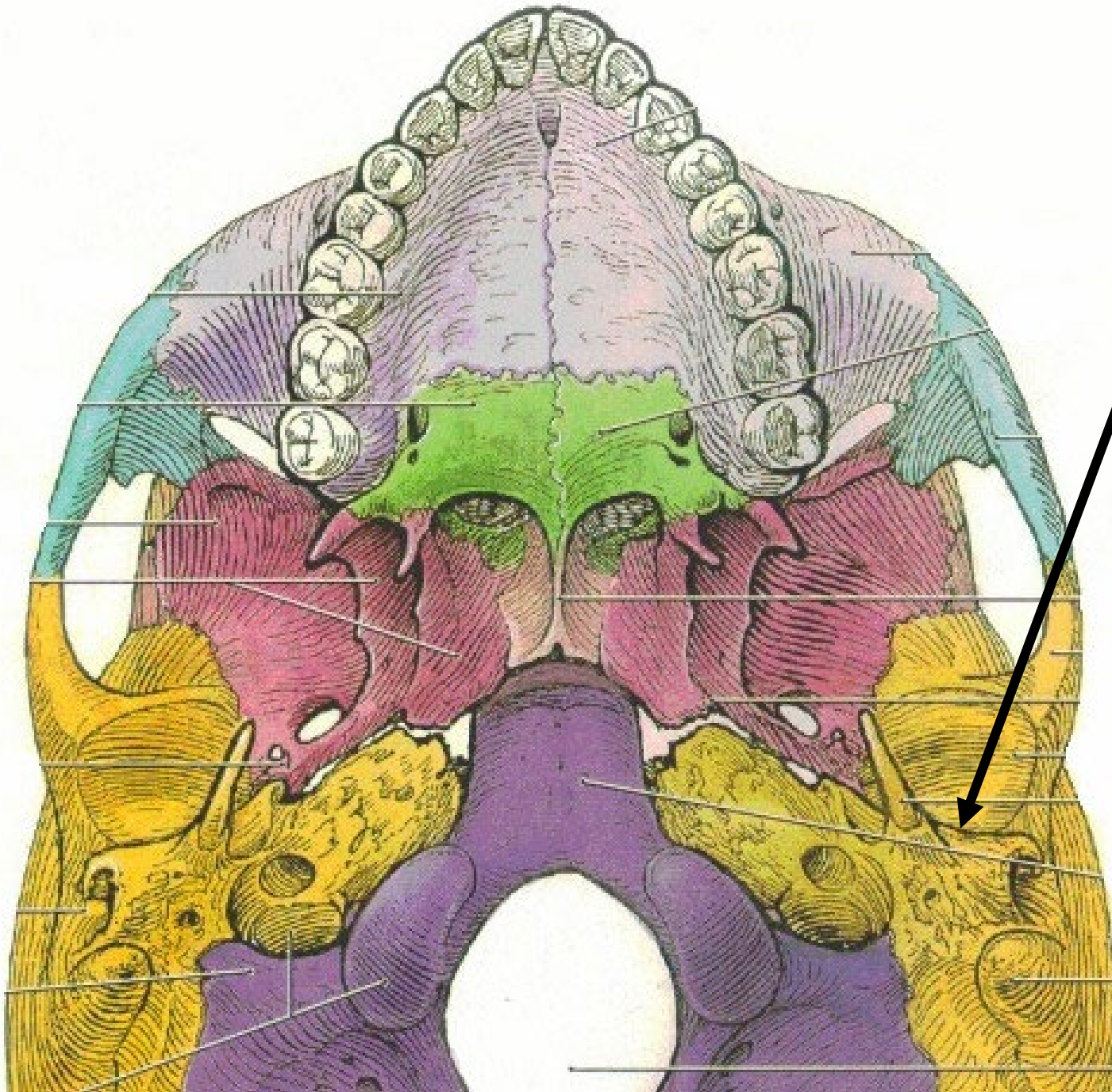
OTOSCOPE VIEW OF TYMPANIC MEMBRANE

**CHORDA
TYMPANI:
TASTE,
VISCERAL
MOTOR
(parasymp)**



**MALLEUS –
manubrium
(handle)**

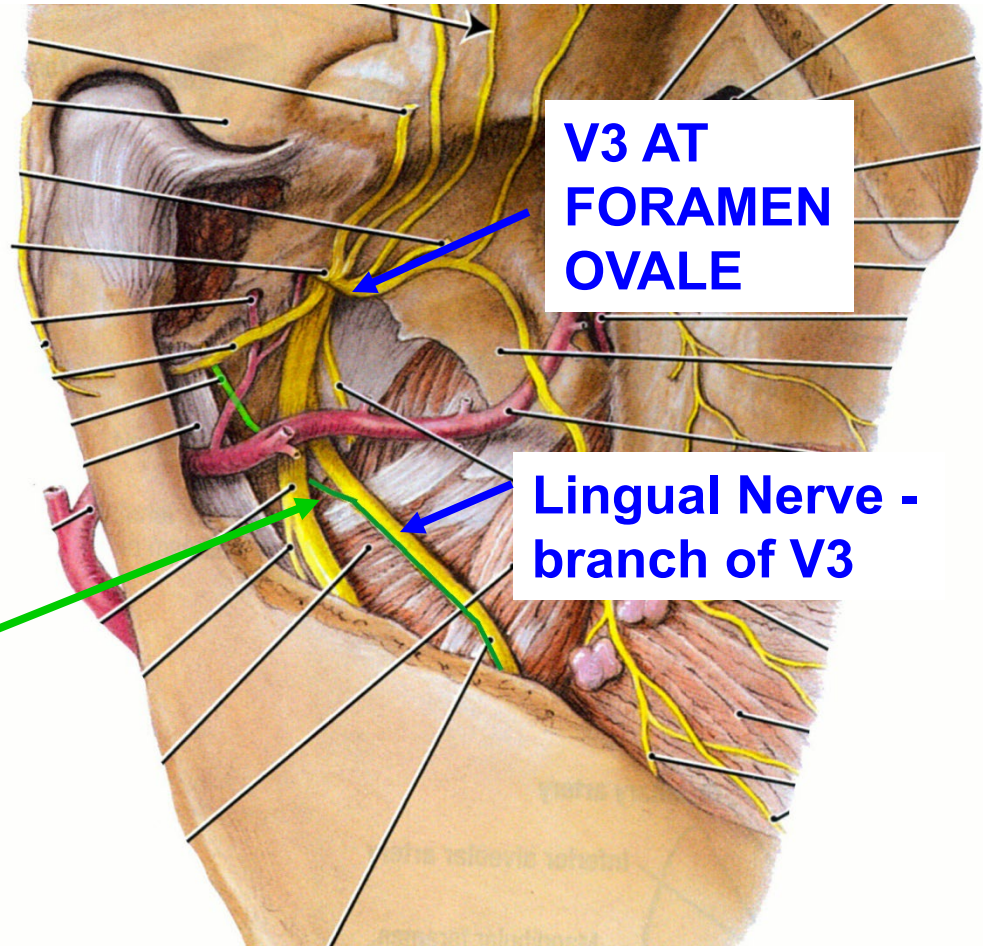
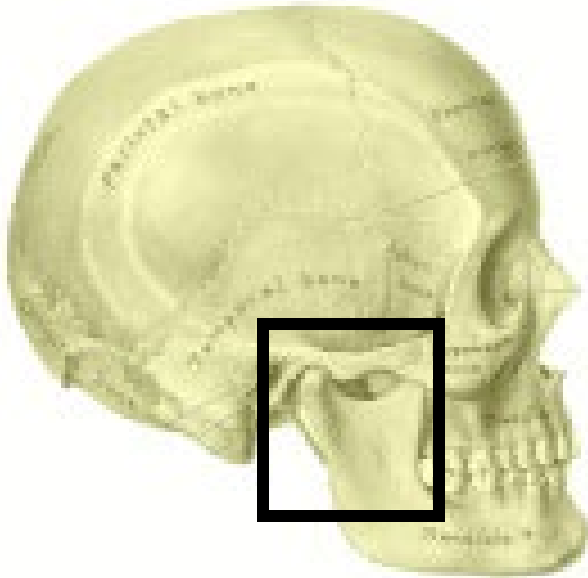

**Lose
taste if
pierce
tympanic
membrane**



PETRO-TYMPANIC FISSURE - for **CHORDA TYMPANI** and **ANT. TYMPANIC ARTERY**

**VII - CHORDA TYMPANI - PARASYMPATHETIC TO
SUBMANDIBULAR AND SUBLINGUAL GLANDS,
TASTE FIBERS TO ANT 2/3 OF TONGUE**

NOSE

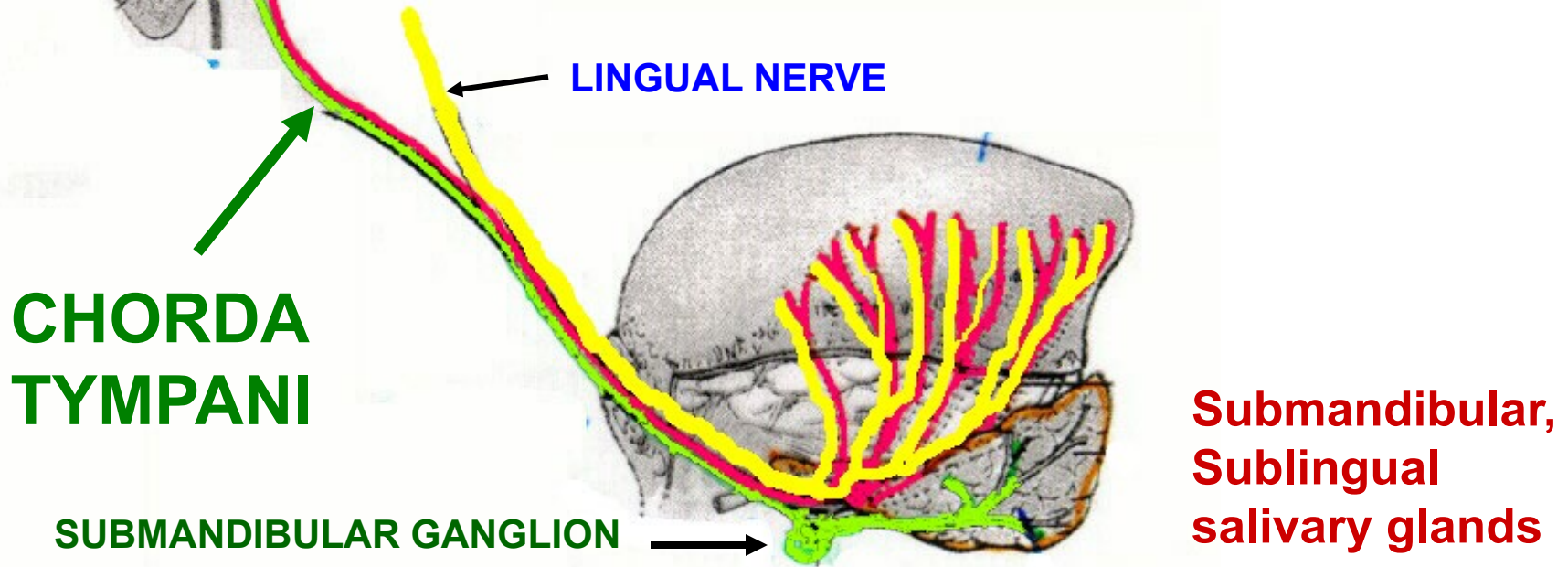


**V3 AT
FORAMEN
OVALE**

**Lingual Nerve -
branch of V3**

**CHORDA
TYMPANI joins
and hitchhikes
with Lingual
Nerve (V3)**

VII - CHORDA TYMPANI JOINS (HITCHHIKES) WITH LINGUAL NERVE



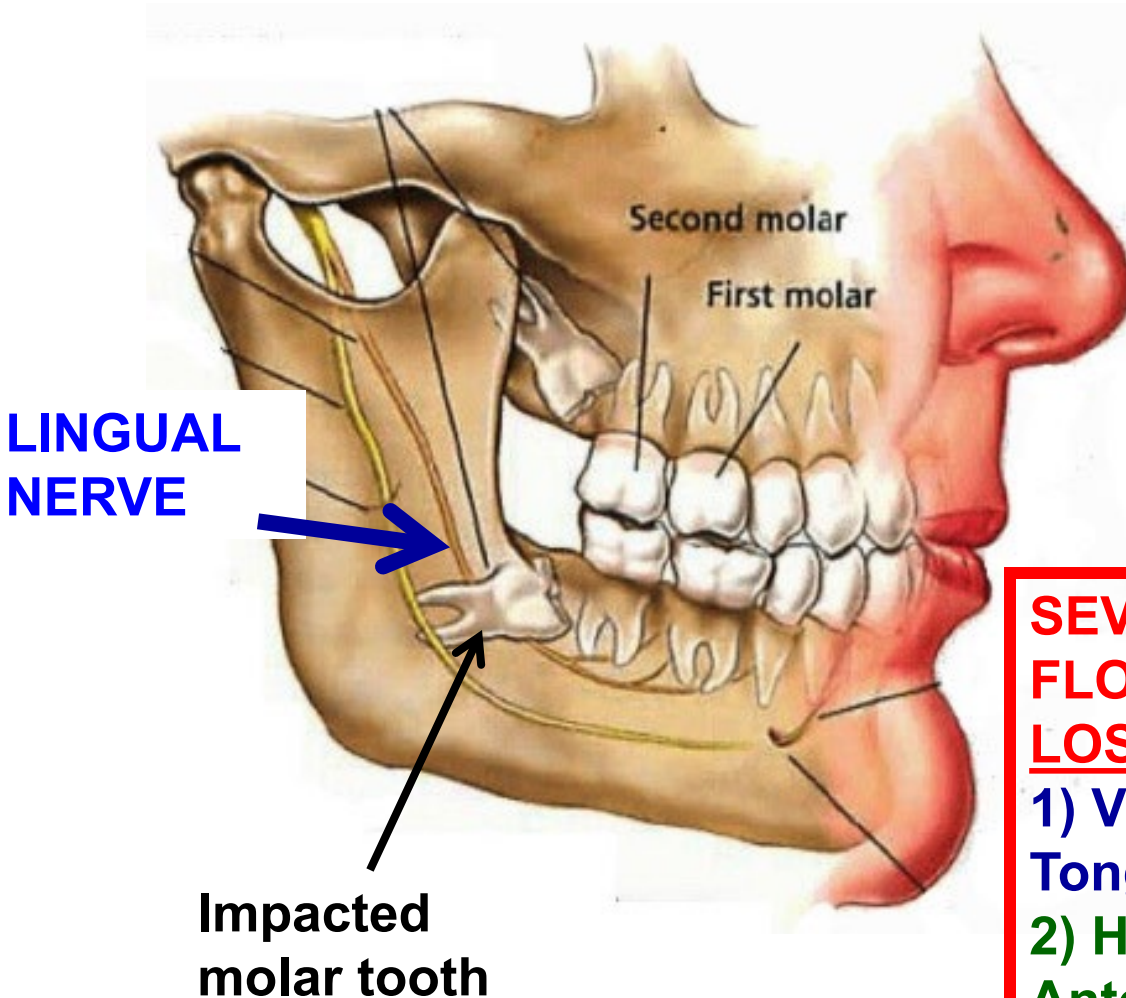
- Parasympathetics - synapse in Submandibular ganglion; post. ganglionics to Submandibular, Sublingual salivary glands
- Taste fibers - continue to taste buds on Ant. 2/3 of tongue

CLINICAL: LINGUAL NERVE (V3) CAN BE DAMAGED IN THE FLOOR OF THE MOUTH


- Lingual nerve courses below mucosa in floor of mouth
- Can readily be damaged during dental extraction of impacted molar tooth
- Also damaged in children: ex. fall with glass pop bottle in mouth

**SEVERING LINGUAL NERVE IN FLOOR OF MOUTH -
LOSE TOUCH AND TASTE:**

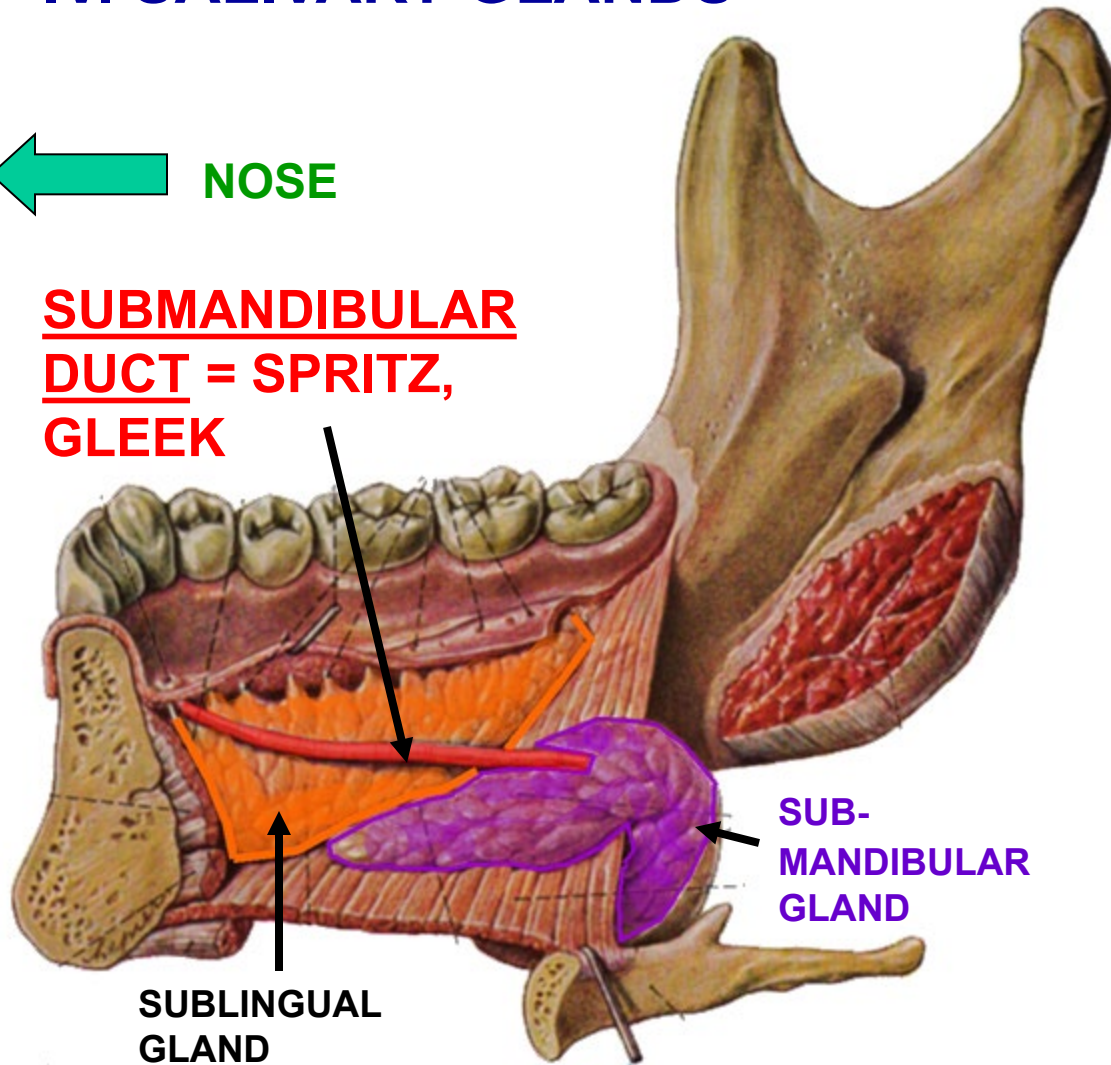
- 1) V - General sensation to Ant. Tongue AND
- 2) Hitchhiking VII - Taste fibers to Anterior Tongue



IV. SALIVARY GLANDS



SUBMANDIBULAR DUCT = SPRITZ, GLEEK




1) SUBMANDIBULAR GLAND - C SHAPED, WRAPS AROUND POST BORDER OF MYLOHYOID; -CAPSULE ATTACHED TO MANDIBLE, DERIVED FROM INVESTING LAYER

SUBMANDIBULAR DUCT- ARISES BETWEEN MYLOHYOID (ANT) & HYOGLOSSUS- POST - OPENS- 1-3 ORIFICES ON SUBLINGUAL PAPILLA

2) SUBLINGUAL GLANDS- LOCATED BETWEEN MANDIBLE & GENIOGLOSSUS -OPENS- 10-12 SMALL DUCTS TO SUBLINGUAL FOLDS (PLICAE SUBLINGUALIS)

SALIVARY GLANDS INNERVATION BY CN VII

NOSE



SUBMANDIBULAR
GANGLION

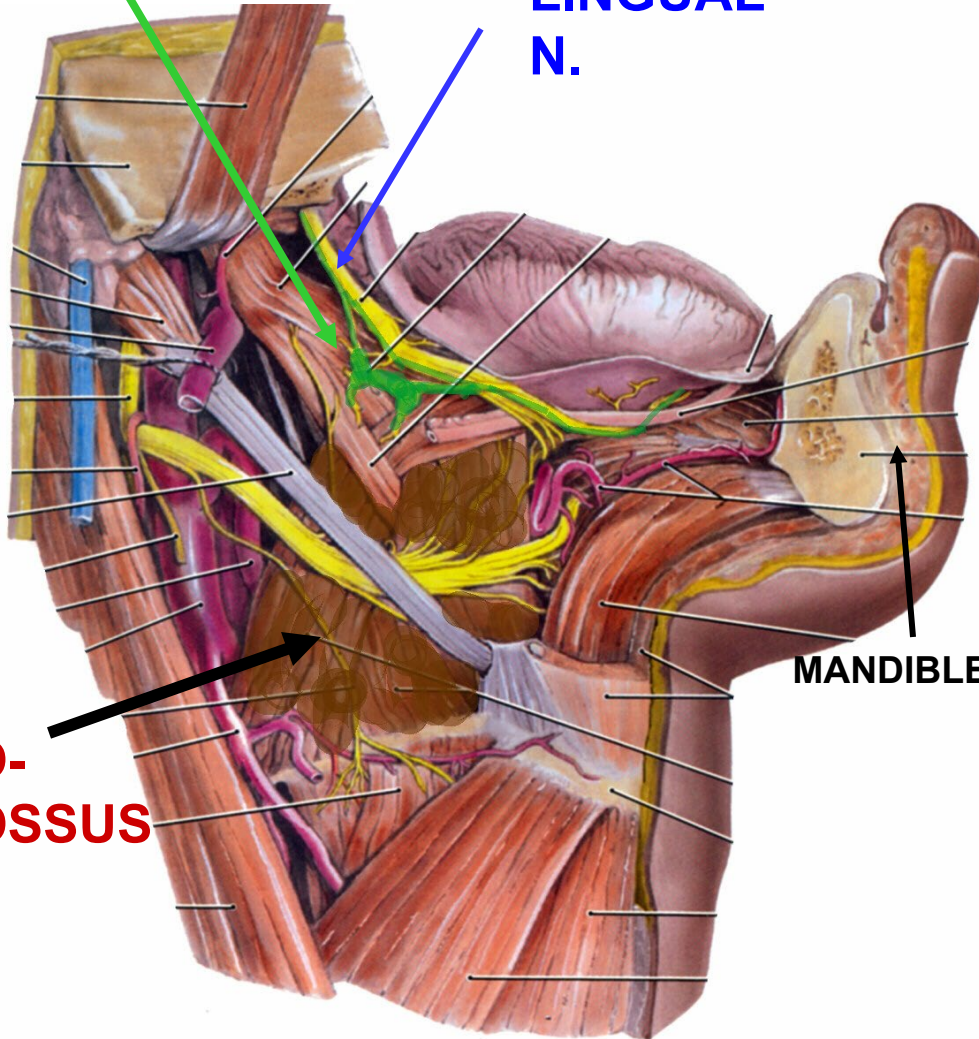
LINGUAL
N.

PARASYMPATHETICS
FROM VII (CHORDA
TYMPANI) HITCHHIKE
WITH LINGUAL NERVE ;

SUBMANDIBULAR
GANGLION (VII) -
SUSPENDED FROM
LINGUAL N., INN
SUBMANDIBULAR &
SUBLINGUAL SALIV.
GLAND

HYO-
GLOSSUS
M.

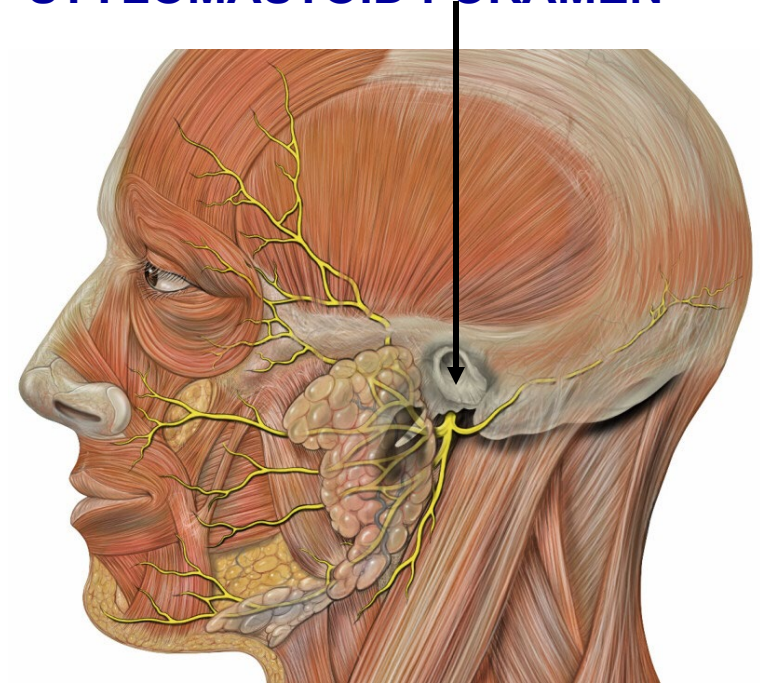
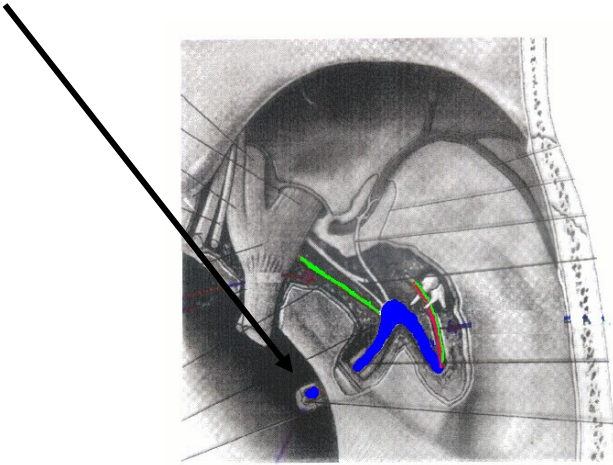
MANDIBLE



FACIAL NERVE (CRANIAL NERVE VII) - MANY BRANCHES INSIDE TEMPORAL BONE

VII - leaves post cranial fossa via Internal Auditory Meatus

VII - EXITS SKULL VIA STYLOMASTOID FORAMEN



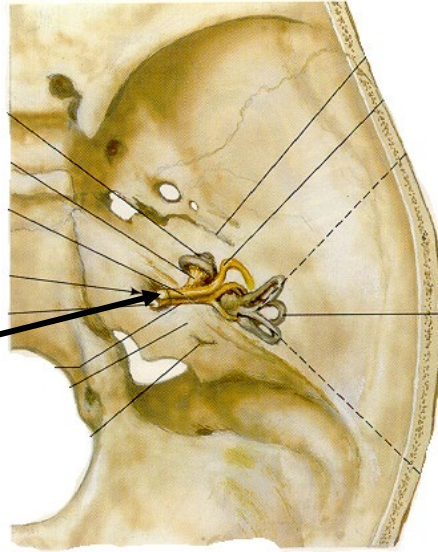
Branches arise in petrous temporal bone:

- 1) Parasympathetics - to Pterygopalatine ganglion - Lacrimal gland, Mucous glands nose palate**
- 2) Taste fibers to ant. 2/3 tongue Chorda tympani - also contains parasymp. Submand., Sub.ling saliv. glands**

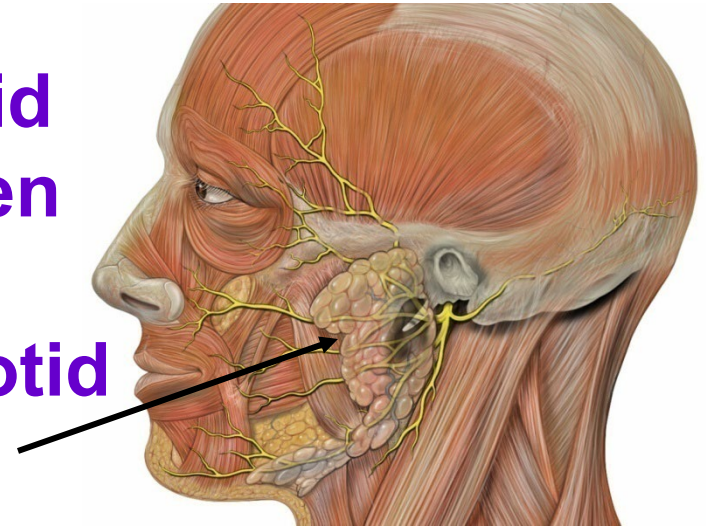
branches only to Muscles Facial Expression, Neck muscles

IV. SYMPTOMS OF DAMAGE TO FACIAL NERVE DEPEND UPON LOCATION

**Int. aud.
meatus**



**Stylo-
mastoid
foramen
or
in Parotid
Gland**



**VII - FACIAL AND
VIII - VESTIBULO-COCHLEAR**

VII - ONLY

**ACOUSTIC NEUROMA (NEURINOMA)-
tumor at INTERNAL AUDITORY ***
MEATUS - BLOCK VII AND VIII**

VIII - auditory/vestibular deficits

**VII - all FACIAL NERVE SYMPTOMS
PRESENT - facial paralysis, loss
of taste, hyperacusia, decrease in
secretion of lacrimal and salivary glands**

**VII - ONLY facial paralysis;
NO loss of taste, NO ***
hyperacusia, NO decrease in
secretion of lacrimal and salivary
glands**

**NO auditory/vestibular deficits;
VIII NOT AFFECTED**