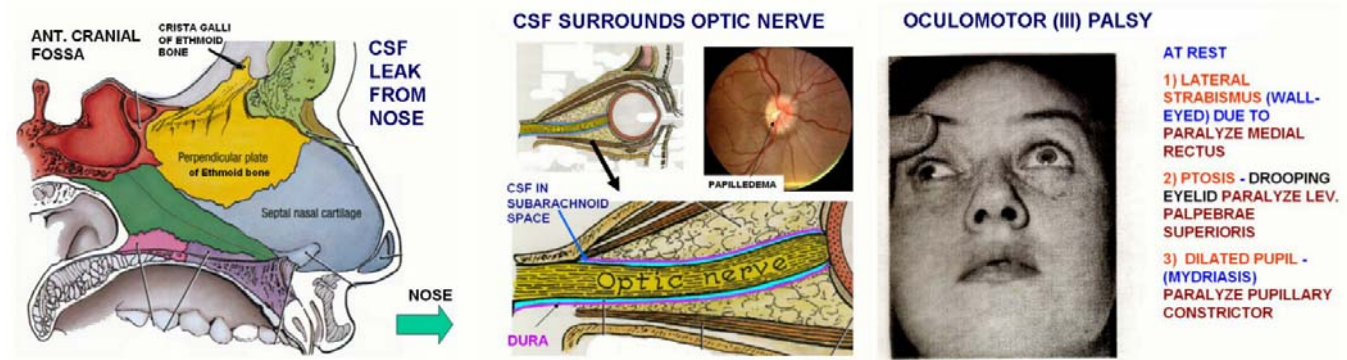


# CLINICAL ANATOMY OF HEAD AND NECK 2025

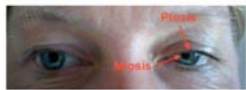© 2025zillmusom

Clinical	Anatomy	Cause	Sign/Symptom
<b>Anterior Cranial Fossa - Cranial nerve I, Nasal Cavity</b>			
<b>Fracture of cribriform plate of ethmoid bone</b>	Nasal septum continuous with crista galli of ethmoid bone; Olfactory nerve passes through cribriform plate of ethmoid bone	Blow to nose; fracture produces <b>continuity between subarachnoid space and nasal cavity</b>	<b>Leakage of CSF from nose</b> ('runny nose'); <b>Decreased sense of smell</b> (hyposmia)
<b>Middle Cranial Fossa - Cranial nerves II-VI Orbit, Eye Movements, Face</b>			
<b>Rapid loss of vision in one eye</b>	Central artery of retina (branch of Ophthalmic artery from Int. Carotid) is normally an end artery with no functional anastomoses (exception: Chorioretinal anastomoses)	<b>Occlusion of Central Artery of Retina</b>	Sudden onset blindness in one eye (one eye only, sign: artery occlusion visible through ophthalmoscope)
<b>Slow loss of vision in one eye</b>	Dura mater and subarachnoid continue over optic nerve; <b>Optic nerve function affected by CSF pressure</b>	<b>Communicating hydrocephalus</b> (many causes)	Decreased visual function both eyes; sign: <b>papilledema</b> in ophthalmoscope view; also other signs of increased intracranial pressure (headache, etc.)
<b>Abducens nerve palsy</b>	Abducens nerve innervates only Lateral Rectus muscle (action: abduction of eye)	Damage Abducens nerve VI (causes ex. increased intracranial pressure, Cavernous sinus thrombosis)	<b>Diplopia and Medial strabismus</b>
<b>Trochlear nerve palsy</b>	Trochlear nerve innervates only Superior Oblique muscle (action: abduct, depress and medially rotate eye)	Damage Trochlear nerve (ex. trauma)	<b>Inability to look down and out</b> (difficulty walking down stairs); <b>Head tilted toward side opposite lesion</b>
<b>Oculomotor nerve palsy</b>	Oculomotor nerve innervates Superior, Medial and Inferior Rectus and Inferior Oblique; part of Levator palpebrae superioris; also provides parasympathetics to pupillary constrictor, ciliary muscles	Damage Oculomotor nerve (frequently idiopathic)	<b>Lateral strabismus, dilated pupil, ptosis; also loss of accommodation (near vision) due to paralysis of ciliary muscles</b>

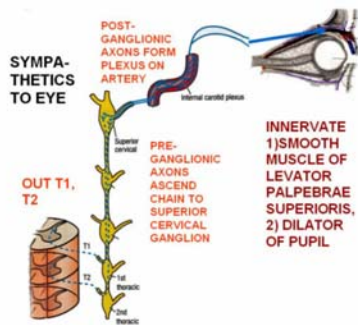


Clinical	Anatomy	Cause	Sign/Symptom
<b>Horner's Syndrome (Dr. Salisbury Lecture)</b>	Sympathetics in head innervate smooth muscle part of Levator Palpebrae Superioris; Pupillary Dilator muscle; sweat glands of skin; <b>Pathway:</b> pre-ganglionic neurons out cord at T1,2; ascend in chain; post-ganglionics in Sup. Cerv. Ganglion; distributed with arteries (ex. Ophthalmic A.)	Block conduction in Sympathetics to head (tumors, etc)	<b>Ptosis</b> (drooping eyelid from smooth muscle part of Levator Palpebrae Superioris); <b>Constricted pupil</b> (miosis due to paralyze Dilator pupillae); <b>Anhidrosis</b> of forehead (denervate sweat glands)
<b>Cavernous sinus thrombosis</b>	Branches of cranial nerves (III, IV, V1, V2, VI) and Internal Carotid artery pass through wall of Cavernous sinus; Cavernous sinus drains ophthalmic veins which anastomose with branches of Facial Vein; veins have no valves	ex. <b>Infection in cav. sinus spread from infection of face (Facial Vein has no/few valves)</b> (angle of nose or upper lip particularly dangerous)	<b>Diplopia</b> (blurred vision) due to disruption of eye movements; increased venous pressure produces <b>engorgement in veins of retina (view in ophthalmoscope) +other symptoms</b>
<b>Epidural Hematoma</b>	<b>Middle Meningeal artery</b> (branch of Maxillary artery that passes through foramen spinosum) supplies bone of calvarium	<b>Blow to side of head (fracture skull in region of pterion)</b>	Patient conscious after accident; loses consciousness within hours; coma, death (Note: <b>hematoma is lens-shaped</b> on CT)
<b>Subdural Hematoma</b>	<b>Bridging veins</b> link Superficial cerebral veins on surface of brain and Superior Sagittal sinus (also other venous sinuses)	<b>Blow to head; in elderly can occur without distinct event</b>	<b>Slow onset</b> of neurological symptoms, headache (often hours to days) (Note: <b>hematoma is crescent-shaped</b> on CT)
<b>Communicating Hydrocephalus due to decreased CSF reabsorption</b>	CSF produce in choroid plexus; reabsorbed from subarachnoid space at arachnoid villi into venous sinuses	In elderly, <b>Calcification of arachnoid villi</b> (arachnoid granulations)	<b>Headache, papilledema</b>

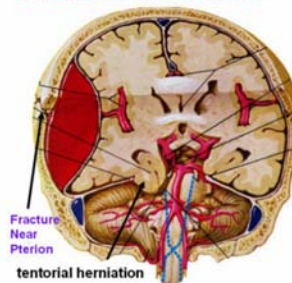
**HORNER'S SYNDROME**



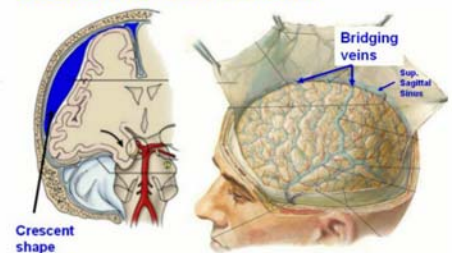
**SYMPTOMS -**  
**PTOSIS** - eyelid droop  
**MIOSIS** - constricted pupil  
**ANHYDROSIS** - lack of sweating



**EPIDURAL HEMATOMA**



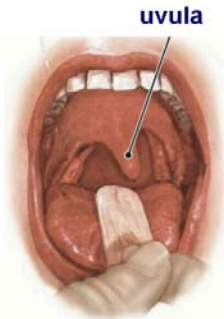**SUBDURAL HEMATOMA**



# CLINICAL ANATOMY OF HEAD AND NECK

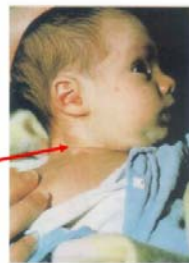Clinical	Anatomy	Cause	Sign/Symptom
Posterior Cranial Fossa - Cranial Nerves VII-XII, face, ear, pharynx, tongue (cont.)			
<b>Loss of function of IX and X</b>	IX is major sensory nerve to pharynx (oropharynx); X is motor to all muscles of pharynx except Stylopharyngeus; all muscles of palate (except Tensor palati)	<b>Tumor at Jugular Foramen</b>	Difficulty in swallowing; <b>Absence of Gag Reflex;</b> (Gag reflex - IX sensory, X motor) <b>Uvula deviates away from side of lesion</b>
<b>Hoarse voice after thyroid surgery</b>	X is motor to all muscles of larynx; also sensory to larynx; Recurrent Laryngeal nerve passes posterior to Thyroid gland with Inf. Thyroid artery; motor to all laryngeal muscles except Cricothyroid	<b>Damage Recurrent Laryngeal nerve during Thyroid surgery</b>	Hoarse voice due to <b>unilateral paralysis of all laryngeal muscles (except Cricothyroid)</b>
<b>Torticollis</b>	XI innervates Sternocleidomastoid and Trapezius	Torticollis can be congenital or acquired	Contracture of Sternocleidomastoid - head is rotated with face directed to opposite side (Note: <b>Trapezius - clinical test for XI - shrug shoulders</b> )
<b>Paralysis of muscles of tongue</b>	XII is motor to all muscles of tongue (no sensory component)	XII hypoglossal nerve palsy	Atrophy of muscles of tongue on one side; <b>protruded tongue deviates toward side of lesion due to Genioglossus) in Lower Motor Neuron Lesion</b>

**LOWER MOTOR NEURON LESION VAGUS (X) - UVULA DEVIATES AWAY FROM SIDE OF LESION**

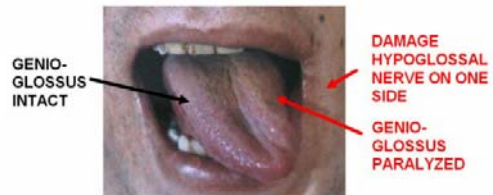

**TORTICOLLIS**

**Contracture of Sternocleidomastoid; Face turned to opposite side**

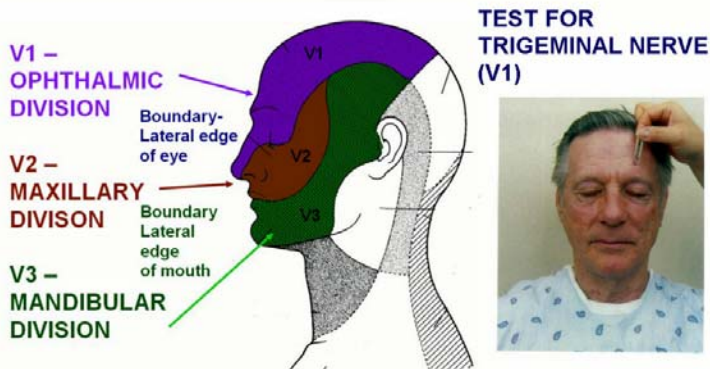


## LOWER MOTOR NEURON LESION XII

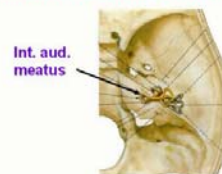


**PROTRUDED TONGUE DEVIATES TOWARD SIDE OF LESION**

Clinical	Anatomy	Cause	Sign/Symptom
Middle Cranial Fossa - Cranial nerves II-VI Orbit, Eye Movements, Face			
<b>Numbness of regions of face</b>	V is major sensory nerve of face and head; <b>Sensory neuron cell bodies</b> are in <b>Semilunar (Trigeminal) Ganglion</b> ; V1 above lateral margin eyelids; V2 eyelids to upper lip; V3 below lateral margins of lips	Many; ex. Trigeminal Anesthesia	Numbness in specific region can be <b>correlated with specific division of V</b>
<b>Pain in external auditory meatus</b> following Facial paralysis	Skin of ear and external auditory meatus receive sensory innervation from V, VII, IX and X	<b>Bell's palsy</b>	Ear ache (following or accompanying Facial paralysis)
<b>Weakness of muscles mastication</b>	Muscles mastication innervated by V3; Lateral Pterygoid opens mouth; all other muscles Mastication close mouth	ex. <b>Tumor at foramen ovale</b>	When open mouth, <b>jaw deviates toward paralyzed side</b>
<b>Facial paralysis (with effect on VIII)</b>	CN VII and VIII exit post. cranial fossa via Internal auditory meatus; VIII ends in temporal bone; VII enters facial canal and gives off branches in temporal bone; 1) parasymp. to Lacrimal gland, mucous glands of nose, palate; 2) Nerve to Stapedius muscle; 3) Chorda tympani - taste to ant. 2/3 of tongue; parasymp. to Submandibular, Sublingual salivary glands	<b>Acoustic neuroma</b>	Loss or reduction of hearing in one ear; <b>Full Facial nerve palsy (Bell's palsy)</b> symptoms: 1) <b>Facial paralysis and loss of Corneal reflex</b> (V1 sensory, VII motor) 2) <b>Loss of taste to ant. 2/3 of tongue</b> 3) <b>Decreased secretion tears and saliva</b> 4) <b>Hyperacusia</b>
<b>Facial paralysis (no effect on VIII)</b>	Facial nerve exits skull via Stylomastoid foramen; only has motor branches after leaving skull	<b>Parotid tumor</b>	<b>Facial paralysis</b> ; Loss of corneal reflex but <b>no loss of taste or decrease in tears or saliva</b> ; <b>no hyperacusia</b>



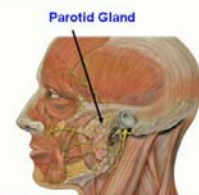**ACOUSTIC NEUROMA (NEURINOMA)**



**Tumor at INTERNAL AUDITORY MEATUS - BLOCK VII AND VIII**

**VII - Bell's Palsy - all FACIAL NERVE SYMPTOMS - facial paralysis, loss of taste, hyperacusia, decrease in secretion of lacrimal and salivary glands**  
**+VIII - auditory/vestibular deficits**

**PAROTID TUMOR**



**BLOCK BRANCHES OF VII**

**VII - ONLY facial paralysis; NO loss of taste, NO hyperacusia, NO decrease in secretion of lacrimal and salivary glands**  
**NO auditory/vestibular deficits**  
**VIII NOT AFFECTED**



### 3) SPINAL REFLEXES AND DIAGNOSIS OF UPPER AND LOWER MOTOR NEURON LESIONS

REFLEX	STIMULUS/SENSE ORGAN(S) EXCITED	RESPONSE	CLINICAL/ABNORMAL RESPONSES
Stretch (Myotatic, Deep Tendon) Reflex	Rapid Stretch of muscle (test: tap on muscle tendon) Excites Muscle Spindle Primary (Ia) and Secondary (II) sensory neurons (NOT Golgi Tendon Organ)	Stretched muscle contracts rapidly (monosynaptic connection); also excite synergist and Inhibit antagonist Note: Gamma motor neurons can enhance stretch reflexes (Gamma dynamic motor neurons specifically enhance Ia sensitivity; tell patient to relax before test)	<u>Hyporeflexia</u> - decrease in stretch reflexes occurs in Lower Motor neuron Diseases, Muscle atrophy etc. <u>Hyperreflexia</u> - (increase) - characteristic of Upper Motor Neuron lesions (ex. spinal cord injury, damage Corticospinal tract); note: <u>Clonus</u> = hyperreflexia with repetitive contractions to single stimulus
Autogenic Inhibition (Inverse Myotatic Reflex)	Large force on tendon excites Golgi Tendon Organ Ib (test: pull on muscle when resisted)	Muscle tension decreases; Also inhibit synergist muscles; excite antagonist muscles	<u>Clasped Knife Reflex</u> - occurs in Upper Motor Neuron lesions - forceful stretch of muscle is first resisted then collapses
Flexor Reflex	Sharp, painful stimulus, as in stepping on nail; Excites - Cutaneous and pain receptors	Limb is rapidly withdrawn from stimulus; protective reflex; also inhibit extensors of same limb and excite extensors of opposite limb (Crossed Extensor Reflex)	<u>Babinski sign</u> - toes extend (dorsiflex) to cutaneous stimulus of sole of foot (normally plantar flex); characteristic of Upper Motor Neuron lesion

### LOWER AND UPPER MOTOR NEURON LESIONS

Lesion	Structure Affected	Symptoms	Examples
Lower Motor Neuron Lesion (Flaccid Paralysis)	Lower Motor Neurons = Alpha Motor neurons with axons that innervate skeletal muscles	Muscle is effectively denervated: 1) Decrease Stretch (Deep Tendon) Reflexes 2) Decreased Muscle Tone 3) Muscle atrophy; Fasciculations (twitches) precede atrophy 4) No Babinski sign	1) Compression of spinal nerve 2) Poliomyelitis - viral infections affecting motor neurons
Upper Motor Neuron Lesion (Spastic Paralysis)	Upper Motor Neurons = All descending neurons that affect Lower Motor Neurons (ex. Corticospinal Reticulospinal neurons)	Disrupt voluntary control and regulation of reflexes (remove inhibition): 1) Increase Stretch (Deep Tendon) Reflexes 2) Increased Muscle Tone 3) No Fasciculations 4) Babinski sign 5) Clasped Knife Reflex	1) Damage to Corticospinal (corticobulbar) tracts - can occur at all levels from cortex to spinal cord (including brainstem)

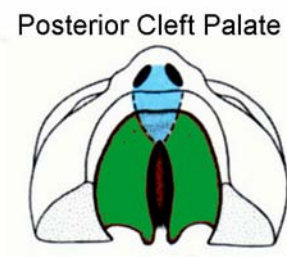
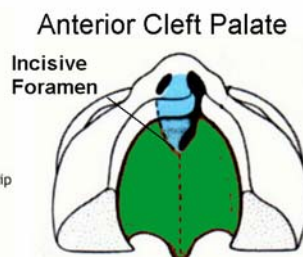
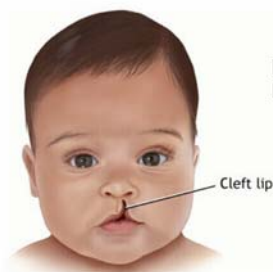
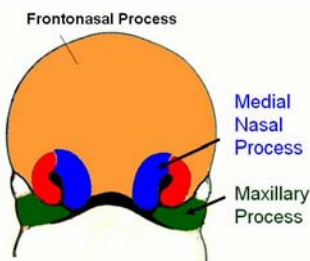
Note: Some diseases produce both Upper and Lower Motor Neuron Symptoms - (ex. ALS Amyotrophic Lateral Sclerosis)

## REFLEXES OF CRANIAL NERVES

REFLEX	STIMULUS	SENSORY	RESPONSE	CLINICAL
Pupillary Light Reflex (II to III)	Test: Shine light in eye	Light detected by Optic Nerve	Excite Constrictor of pupil of eye (III Short Ciliary nerves (Ciliary Ganglion, parasympathetic))	Extensively used to check CN II; Absence of Pupillary Light Reflex can indicate catastrophe (brain herniation)
Corneal Reflex (V to VII)	Touch cornea of eye with cotton	Touch detected by Long Ciliary nerves (V1), Somatic sensory	Close eye (VII to Orbicularis Oculi muscle) Branchiomotor	Absence of Corneal Reflex; Test for damage to V1 sensory, VII motor
Gag Reflex (IX to X)	Test: Touch posterior tongue, oropharynx;	Excites Visceral Sensory endings in Glossopharyngeal N. (IX)	Excite muscles of pharynx, palate; Vagus N. (X), Branchiomotor	Other symptoms of Vagus damage (X); Patient Say's Ahh: soft palate not elevated on ipsilateral side (paralyze Levator Palati); uvula deviated away from side of lesion
Jaw Jerk Reflex Stretch (Deep Tendon) Reflex (V to V)	Test: tap down on mandible; Stretch muscles of mastication (ex. Masseter)	Excites Muscle Spindle sensory neurons in Trigeminal nerve (V)	Contract muscles that elevate mandible Motor - V3	<u>Hyporeflexia</u> - indicates Trigeminal nerve damage

## CLINICAL EMBRYOLOGY OF HEAD AND NECK

Clinical Condition	Normal development	Abnormal	Signs/ Symptoms	Treatment
<b>Cleft Lip</b> (cheiloschisis)	Fusion of medial nasal and maxillary processes forms upper lip	<b>Failure of fusion of medial nasal and maxillary processes</b>	Cleft at philtrum of upper lip	Surgical repair
<b>Cleft Palate</b> (palatoschisis)	<b>Anterior</b> - Fusion of medial nasal processes (Primary palate) and maxillary processes (Secondary Palate); <b>Posterior</b> - Secondary palate formed by fusion of Maxillary processes of two sides	<b>Failure of fusion</b>	<b>Anterior</b> - Cleft <u>anterior to Incisive foramen</u> ; <b>Posterior</b> - Cleft <u>posterior to Incisive foramen</u>	Treatment: Surgical repair
<b>Malformation of nasolacrimal duct</b> (dacryostenosis)	Duct forms as cord between maxillary and frontonasal processes; extends from lacrimal sac (at medial canthus of eye) to nasal cavity (inferior meatus)	<b>Cord fails to canalize</b>	Continuous flow of tears over lower lid onto face	Surgical repair
<b>First Arch (Treacher Collins) Syndrome</b>	First brachial arch forms skeletal elements: 1) malleus, incus 2) contributes to mandible (Meckel's cartilage)	<b>Neural crest cells do not migrate into Arch 1</b>	1) Mandibular hypoplasia 2) Conductive hearing loss 4) Facial malformation	Some surgical repair
<b>Thyroglossal duct cysts</b>	Thyroid forms as evagination at foramen cecum of tongue; tissue migrates ant. to Hyoid bone in midline of neck to location below Cricoid cartilage	<b>Glandular tissue or cysts develop anywhere along path of migration</b>	Mass in <b>midline</b> of neck	Surgical removal (remove tract to tongue)
<b>Abnormal location/ Accidental Removal of parathyroid glands</b>	Normally posterior to thyroid gland or embedded in it; develop from branchial pouches 3 and 4 Inferior parathyroid - pouch 3 Superior parathyroid - pouch 4	<b>Can be located within thyroid gland or ectopic</b>	Normally no symptoms; calcium imbalance If accidentally remove ( during thyroid surgery)	Treat calcium imbalance pharmacologically, etc.



# BRANCHIAL ARCHES AND DERIVATIVES

ARCH (NERVE)	SKELETAL	LIGAMENTS	MUSCLES
First (V)	1) Malleus 2) Incus	1) Ant. ligament of malleus 2) Spheno-mandibular ligament	1) Muscles of Mastication 2) Tensor tympani 3) Tensor palati 4) Mylohyoid 5) Ant. belly of Digastric
Second (VII)	1) Stapes 2) Styloid process 3) Hyoid bone - lesser horn, upper half of body	Stylohyoid ligament	1) Muscles of Facial Expression 2) Stapedius 3) Stylohyoid 4) Post. belly of Digastric
Third (IX)	Hyoid bone - greater horn, lower half of body	-----	Stylopharyngeus
Fourth (X)	Cartilages of Larynx	-----	1) All muscles of Larynx 2) All muscles of Pharynx (except Stylopharyngeus) 3) All muscles of Soft Palate (except Tensor palati)
Sixth (XI)	-----	-----	1) Sternocleidomastoid 2) Trapezius

## STRUCTURES DERIVED FROM BRANCHIAL POUCHES, CLEFT AND MEMBRANE: BRANCHIAL 'CLEFT' CYSTS (FISTULI = channels from pharynx to skin)

POUCH	FORMS	CLINICAL
First	1) Auditory tube 2) Tympanic cavity	First Branchial 'Cleft' cyst - tract to external auditory meatus or auditory tube
Second	Lining (crypts) of palatine tonsils	Second Branchial 'Cleft' cyst - tract to tonsillar fossa (palatine tonsils) - <b>MOST COMMON CYST</b>
Third	1) Inferior parathyroid gland 2) Thymus	Third Branchial 'Cleft' cyst - tract to thyrohyoid membrane or piriform recess
Fourth	1) Superior parathyroid gland 2) C-cells of Thyroid	Rare

Note: Pouch 3 structures migrate below (caudal) to Pouch 4 structures.

Note: **Location of Cysts and Fistuli - in lateral neck, anterior to Sternocleidomastoid muscle**

Note: **First Branchial Cleft forms Ext. Auditory Meatus; First Branch. Membrane = Tympanic Membrane**

