

# **DISCUSSION SESSION 5: GROSS ANATOMY**

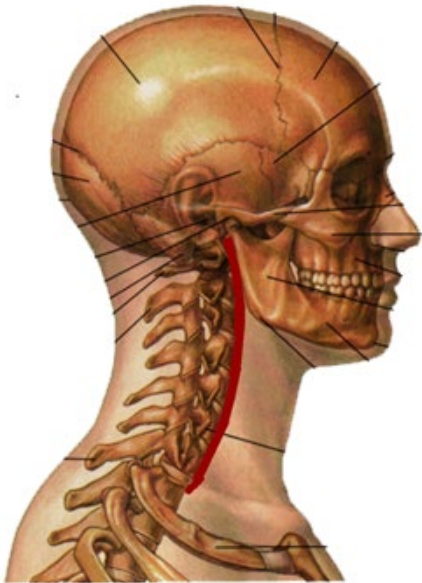
## **NN BLOCK**

**Discuss Neck (I and II),  
Nasal Cavity  
Oral Cavity,**

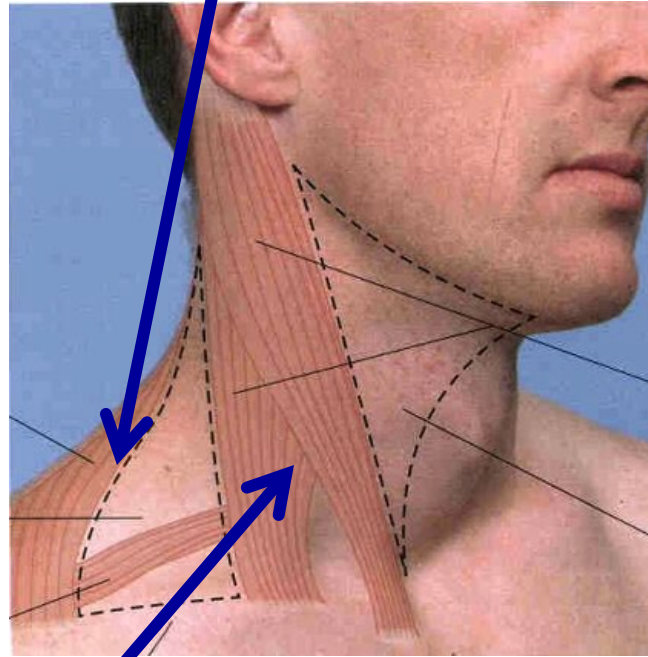
# NECK

## MUSCLES OF NECK - MAJOR LANDMARKS

### NECK - VERTEBRA AND MUSCLES



### TRAPEZIUS



### STERNOCLEIDO- MASTOID

### LATERAL NECK - POSTERIOR TRIANGLE

1) STERNOCLEIDO-  
MASTOID

2) TRAPEZIUS

Innervation - CN XI -  
Accessory Nerve

### CLINICAL TEST OF ACCESSORY NERVE (CN XI) -

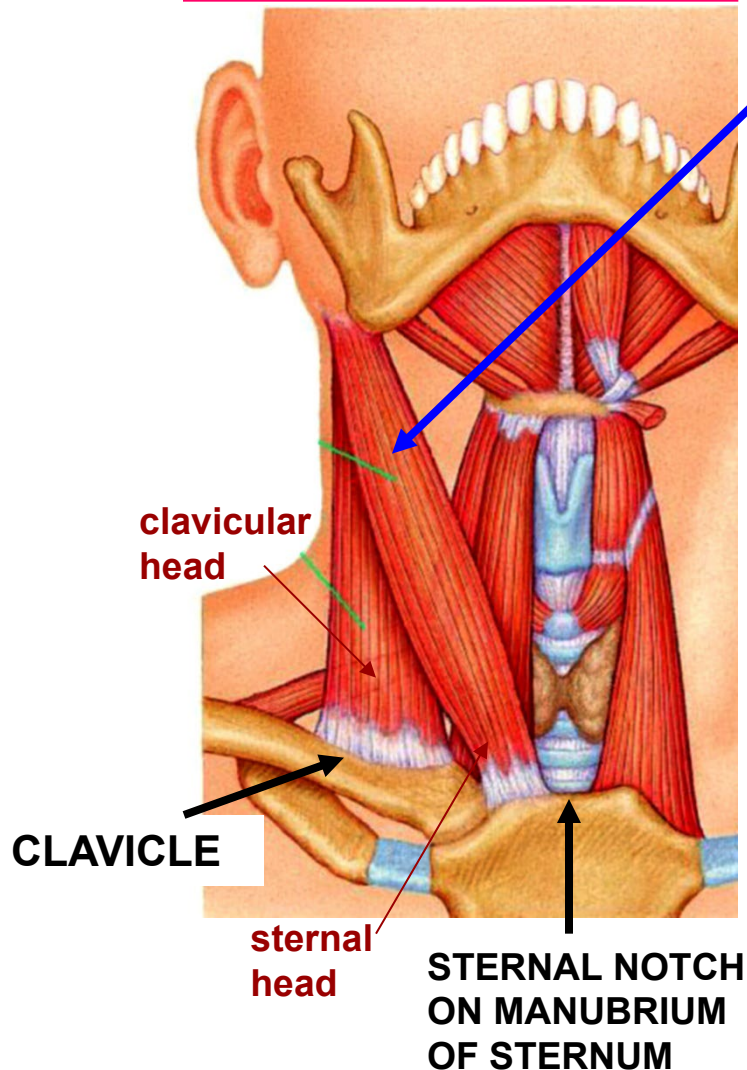
1) 'Shrug' shoulders  
- tests Trapezius

2) Rotate (Flex) head  
- tests

Sternocleidomastoid

# MUSCLES OF NECK - MAJOR LANDMARKS

**MOST IMPORTANT  
LANDMARK IN NECK**



## 1. STERNO-CLEIDOMASTOID

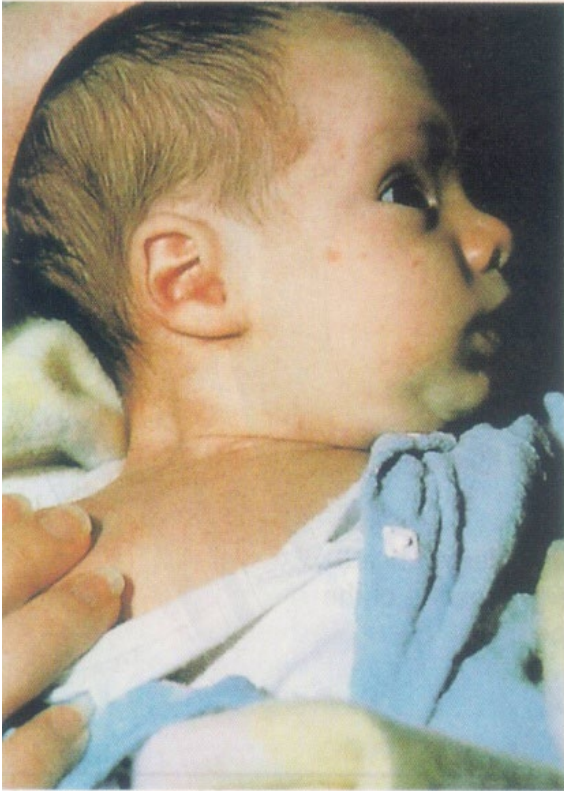
Origin - Two heads: 1) Sternum; 2) Clavicle; Insert - Mastoid process of temporal bone  
Act -

Bilateral - flex head;  
Unilateral rotate head, face directed to opposite side

(MASTOID MOVES TOWARD STERNUM)

Inn - CN XI Accessory.

# TORTICOLLIS = twisted neck



**Congenital  
Torticollis**

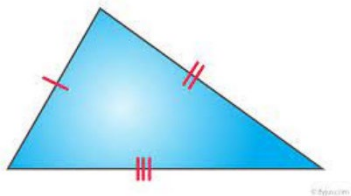
**TORTICOLLIS – twisted neck**

**1- Congenital - Contracture of Sternocleidomastoid (continuous contraction) - Neck rotated so face directed to Opposite Side**

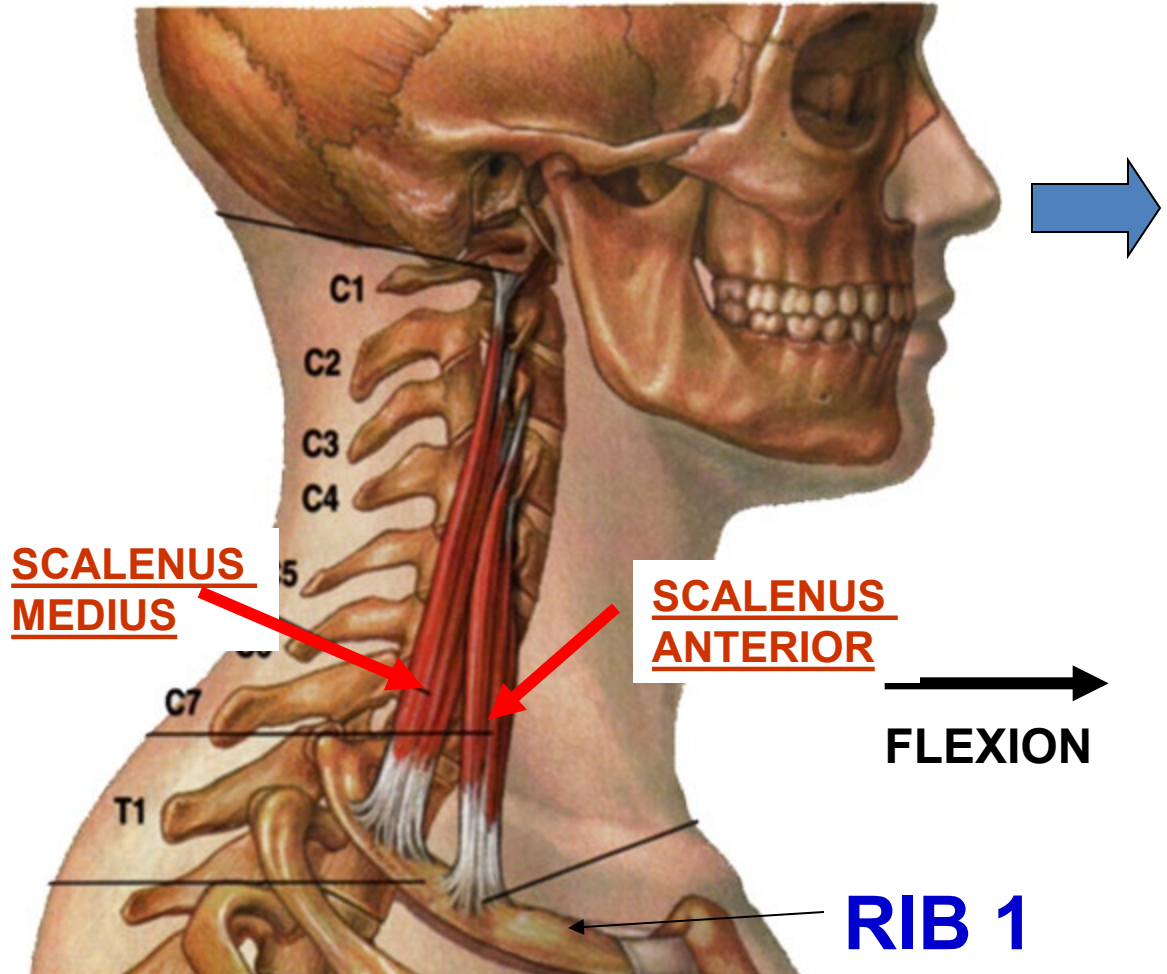
**2- Damage CN XI - Weakness in turning neck to opposite side (test against resistance)**

# MUSCLES OF NECK – SCALENE MUSCLES

## SCALENUS ANTERIOR AND SCALENUS MEDIUS



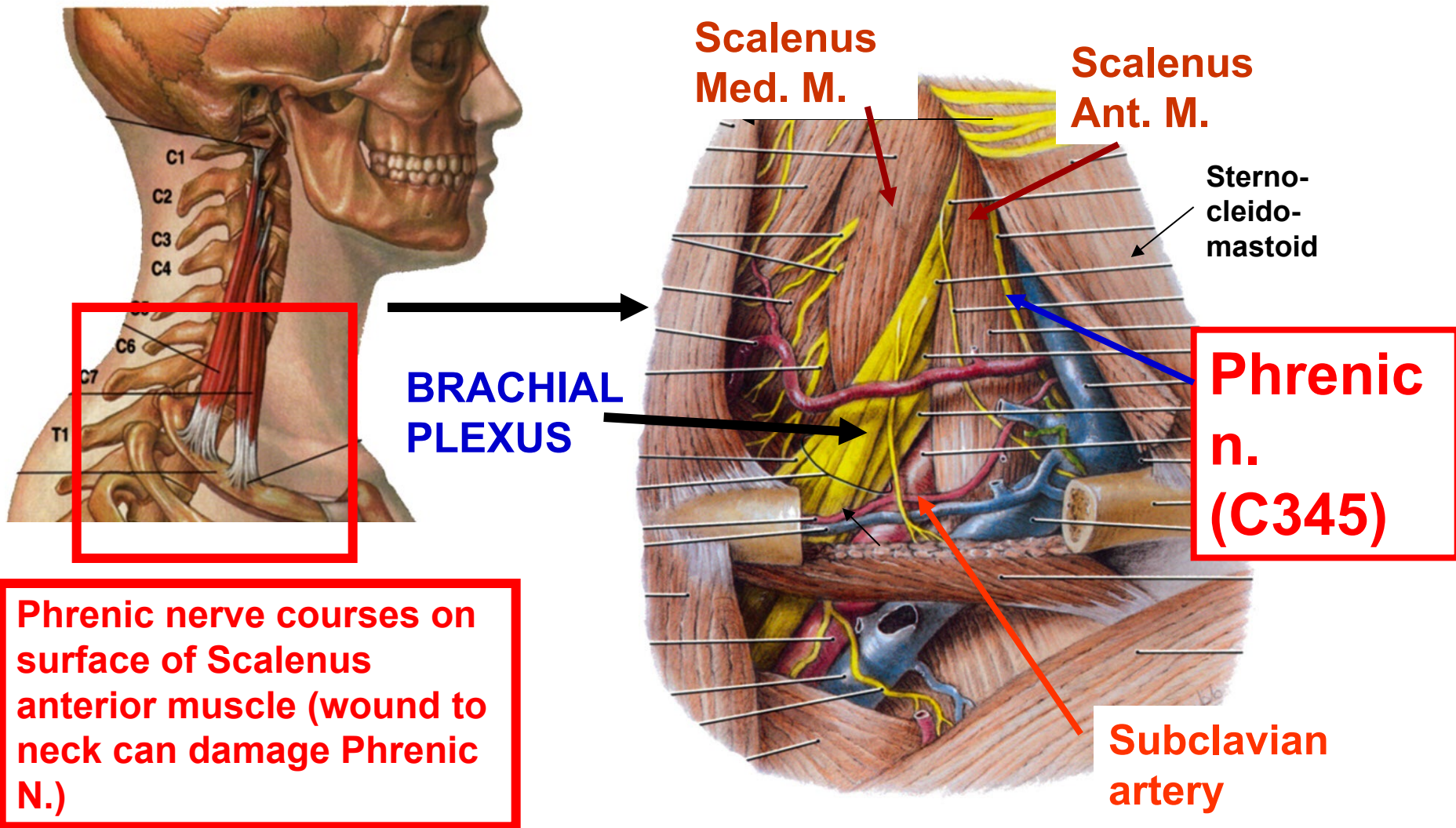
SCALENE TRIANGLE - EACH SIDE DIFFERENT LENGTH





# SCALENUS ANTERIOR AND SCALENUS MEDIUS ARE IMPORTANT LANDMARKS

- **Brachial Plexus**, Subclavian Artery pass between Scalenus Ant. and Med.;
- **Phrenic nerve** (to Diaphragm) **courses on Scalenus Anterior**



# MUSCLES OF NECK – HYOID MUSCLES



**SUPRAHYOID  
MUSCLES**

MYLOHYOID

DIGASTRIC



**INFRAHYOID  
MUSCLES**

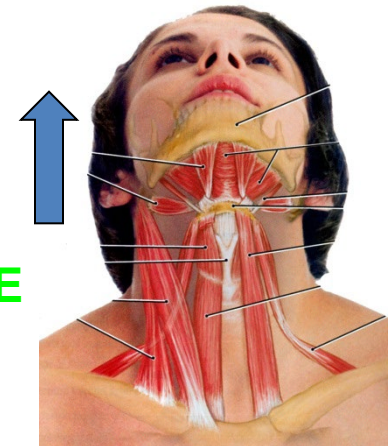
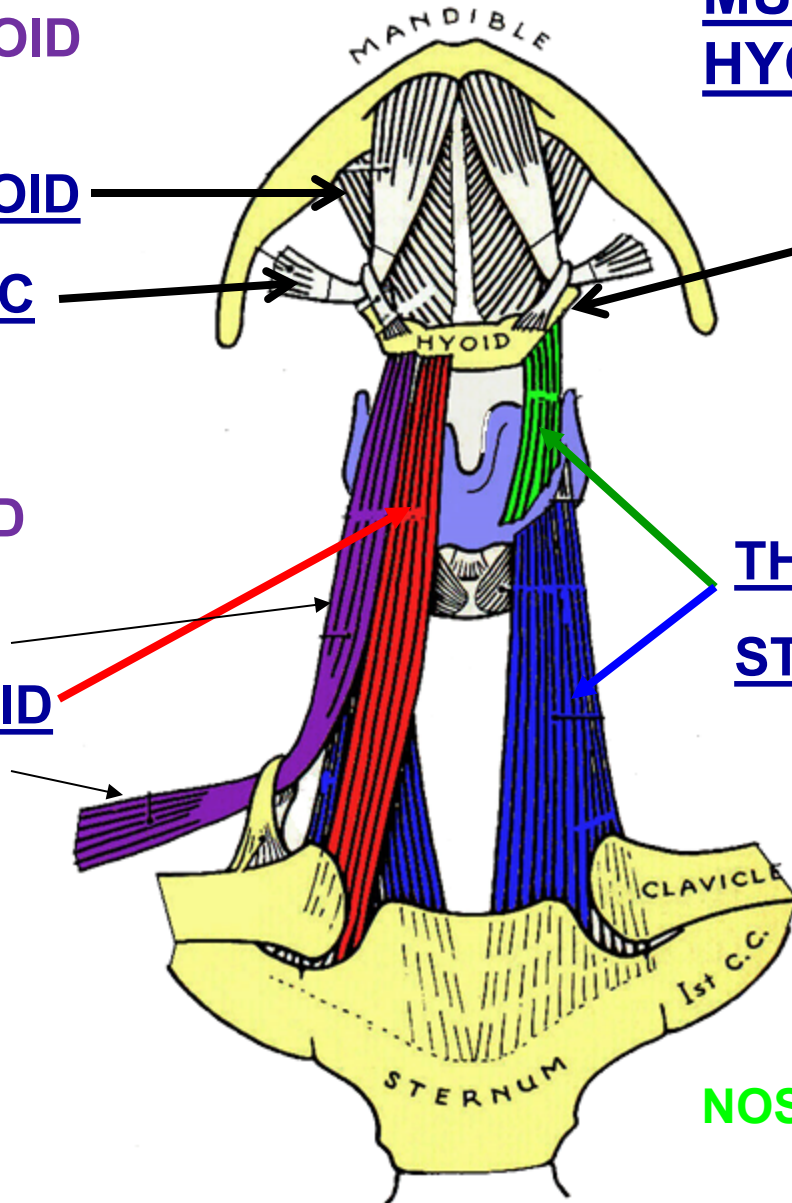
STERNOHYOID

OMOHYOID

HYOID BONE -  
BRANCHIAL  
ARCHES 2 AND 3 -  
SWALLOWING,  
ATTACHMENT OF  
TONGUE

THYROHYOID

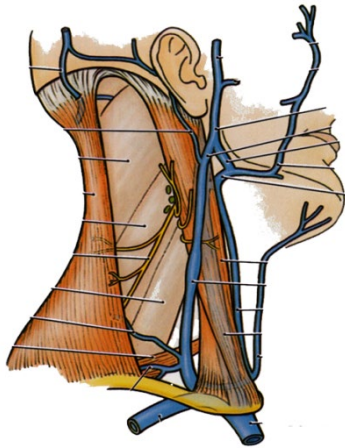STERNOHYOID



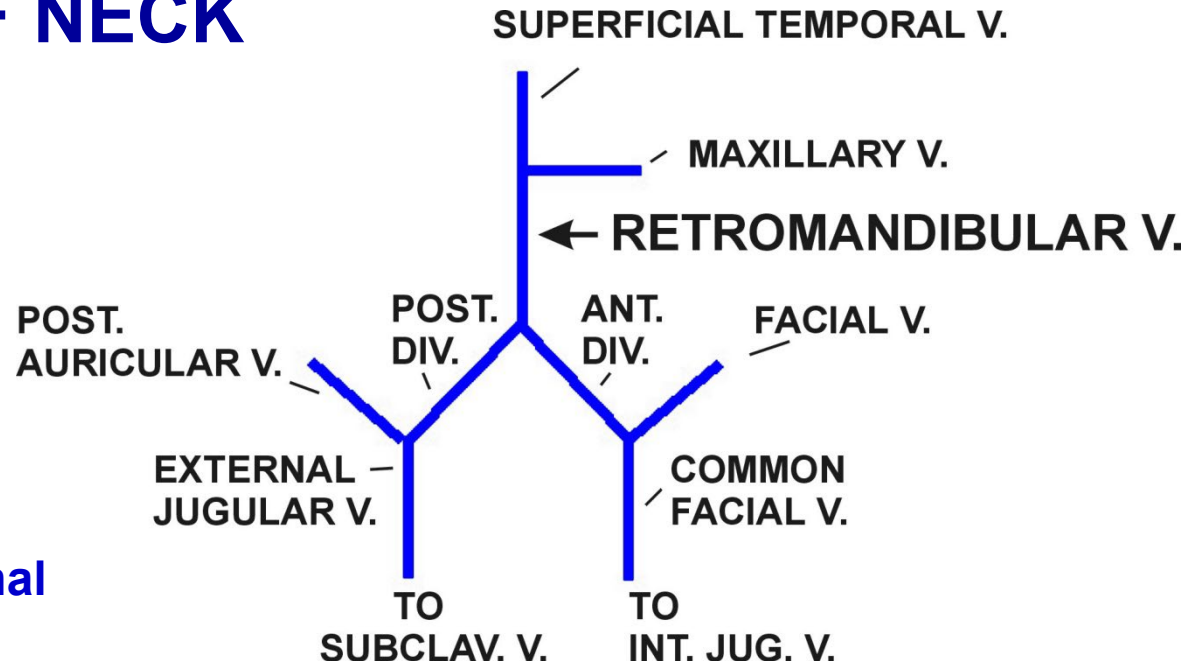
**ORIENT -  
HEAD  
TILTED  
BACK**

**NOSE**

# VEINS OF NECK



**Large External Jugular V.**



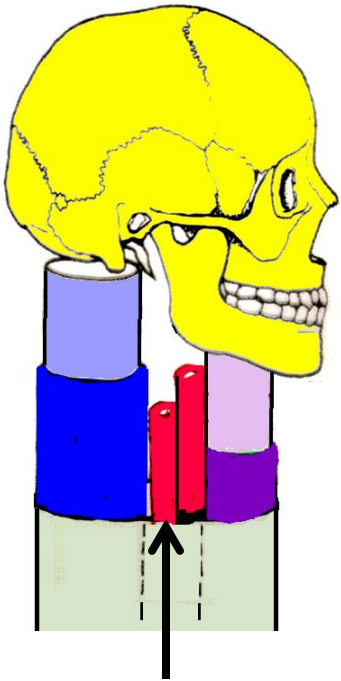
**Large Anterior Jugular V.**

**EXTERNAL JUGULAR V. - ON SURFACE OF STERNOCLEIDOMASTOID; NOT IN CAROTID SHEATH**  
**INTERNAL JUGULAR V. - DEEP TO STERNOCLEIDOMASTOID; IN CAROTID SHEATH**

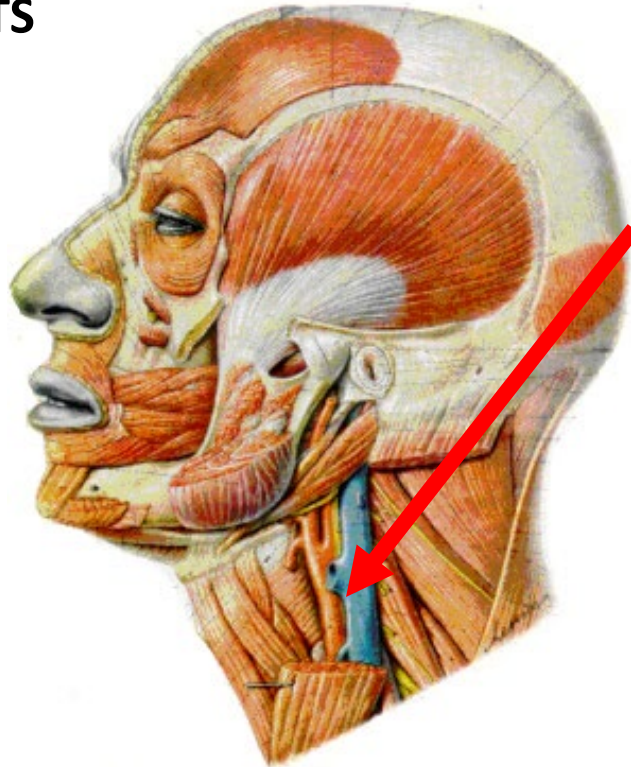


# NECK - is compartmentalized by Fascia (connective tissue)

## FASCIAL COMPARTMENTS OF NECK



**CAROTID SHEATH**



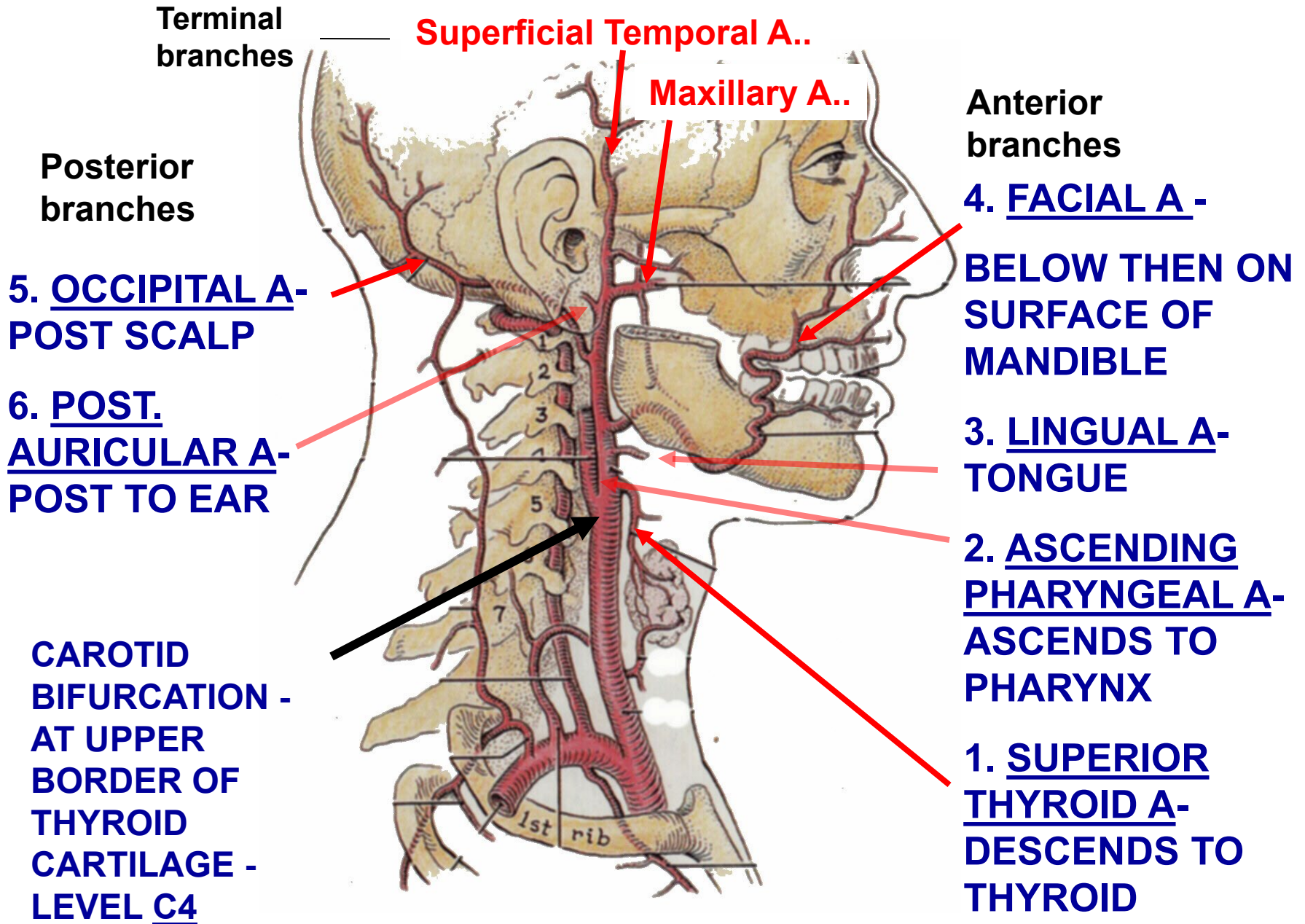
Lateral Compartment-  
lateral and posterior to  
pharynx

Contained in Carotid  
Sheath

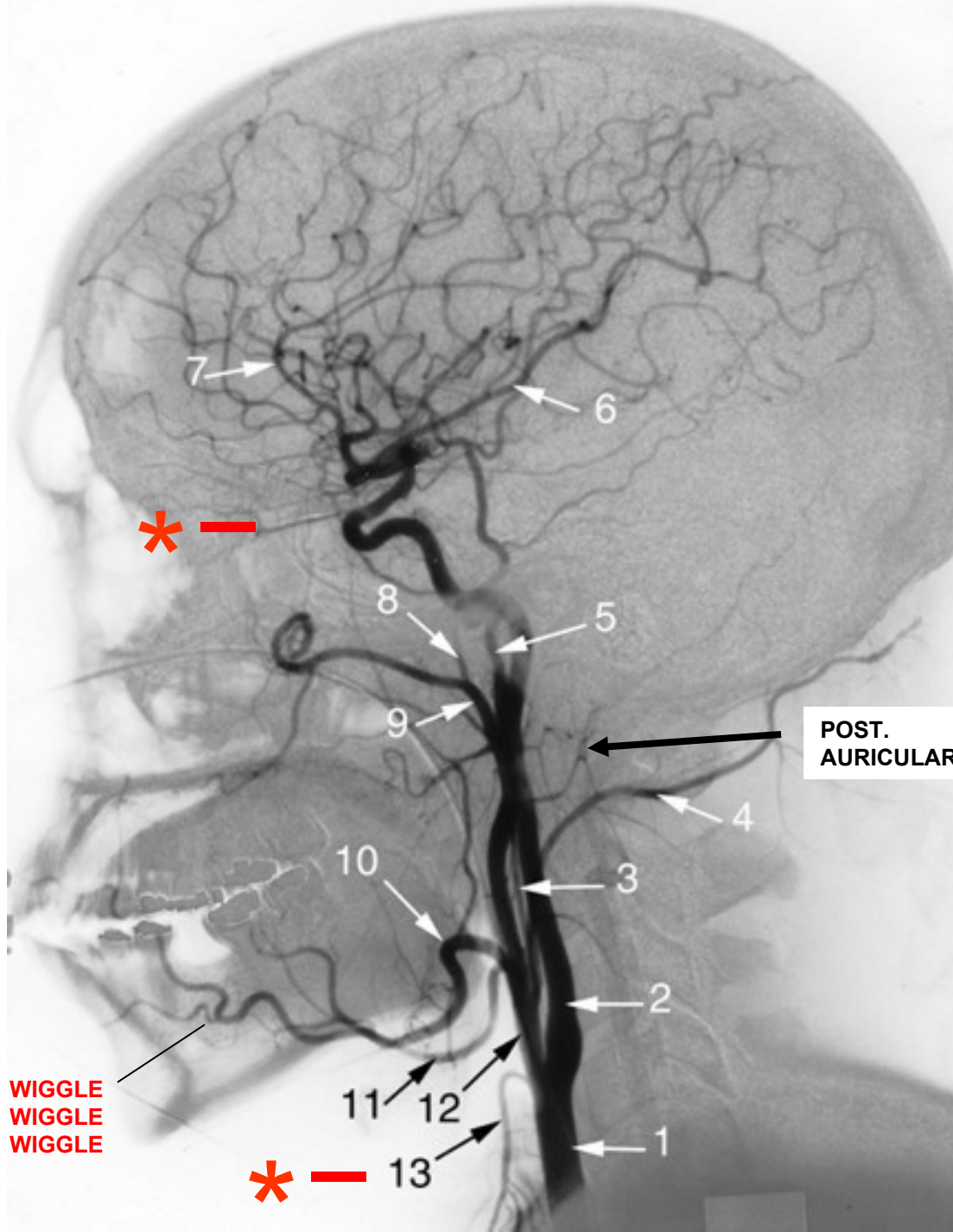
- 1) Common and Internal Carotid arteries
- 2) Internal jugular vein
- 3) Vagus nerve

Note: Sympathetic chain  
is posterior to (NOT IN)  
Carotid Sheath

# EXTERNAL CAROTID ARTERY



**NOT ON ZILL  
QUESTIONS IN  
NEXT EXAM**



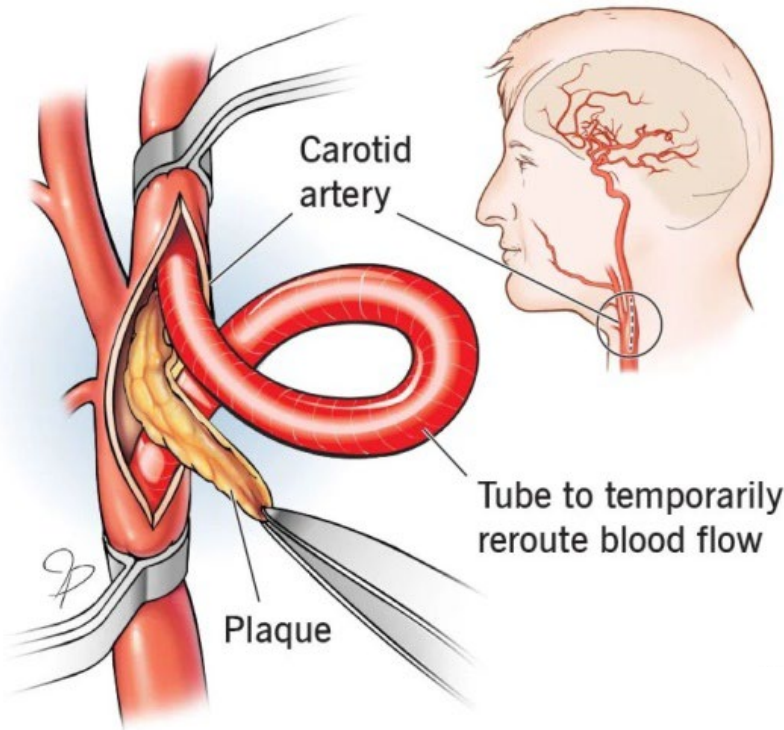
1. COMMON CAROTID
2. INTERNAL CAROTID
3. ASCENDING PHARYNGEAL
4. OCCIPITAL
5. SUPERFICIAL TEMPORAL
6. MIDDLE CEREBRAL
7. ANTERIOR CEREBRAL
8. MIDDLE MENINGEAL
9. MAXILLARY
10. FACIAL
11. LINGUAL
12. EXTERNAL CAROTID
- 13. SUPERIOR THYROID**

**\*- OPHTHALMIC ARTERY  
ARISING FROM CAROTID  
SIPHON**



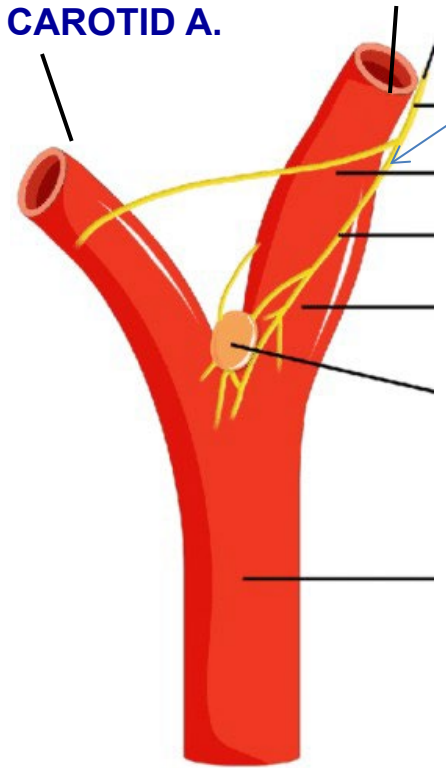
# CAROTID ENDARTERECTOMY - remove plaque from Carotid Artery

Carotid Endarterectomy



EXT. CAROTID A.

INT. CAROTID A.



**GLOSSOPHARYNGEAL N. (CN IX)**

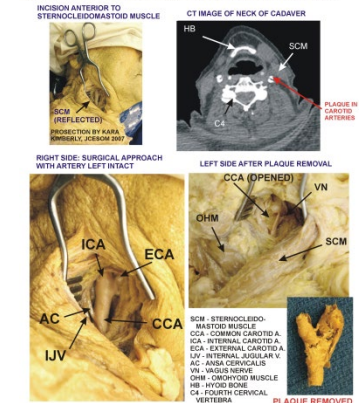
**CAROTID SINUS - BARORECEPTION (PRESSURE)**

**CAROTID BODY - CHEMORECEPTION**

**COMMON CAROTID A.**

PROSECTIONS

SURGICAL PROSECTIONS: CAROTID ENDARTERECTOMY  
 SURGICAL APPROACH FOR CAROTID ENDARTERECTOMY PERFORMED ON BOTH RIGHT AND LEFT SIDES; PLAQUE WAS REMOVED ON LEFT SIDE AND DISSECTION EXTENDED TO SHOW ANATOMICAL RELATIONSHIPS WITH SURROUNDING STRUCTURES



- Endarterectomy can damage Vagus nerve CN X (in Carotid Sheath)
- also damage CN IX - innervate Carotid Body, Sinus - disrupt Cardiovascular function
- incision also damage CN XII



# THYROID GLAND

## THYROID EXAMINATION LANDMARKS

PALPATE

PLATE

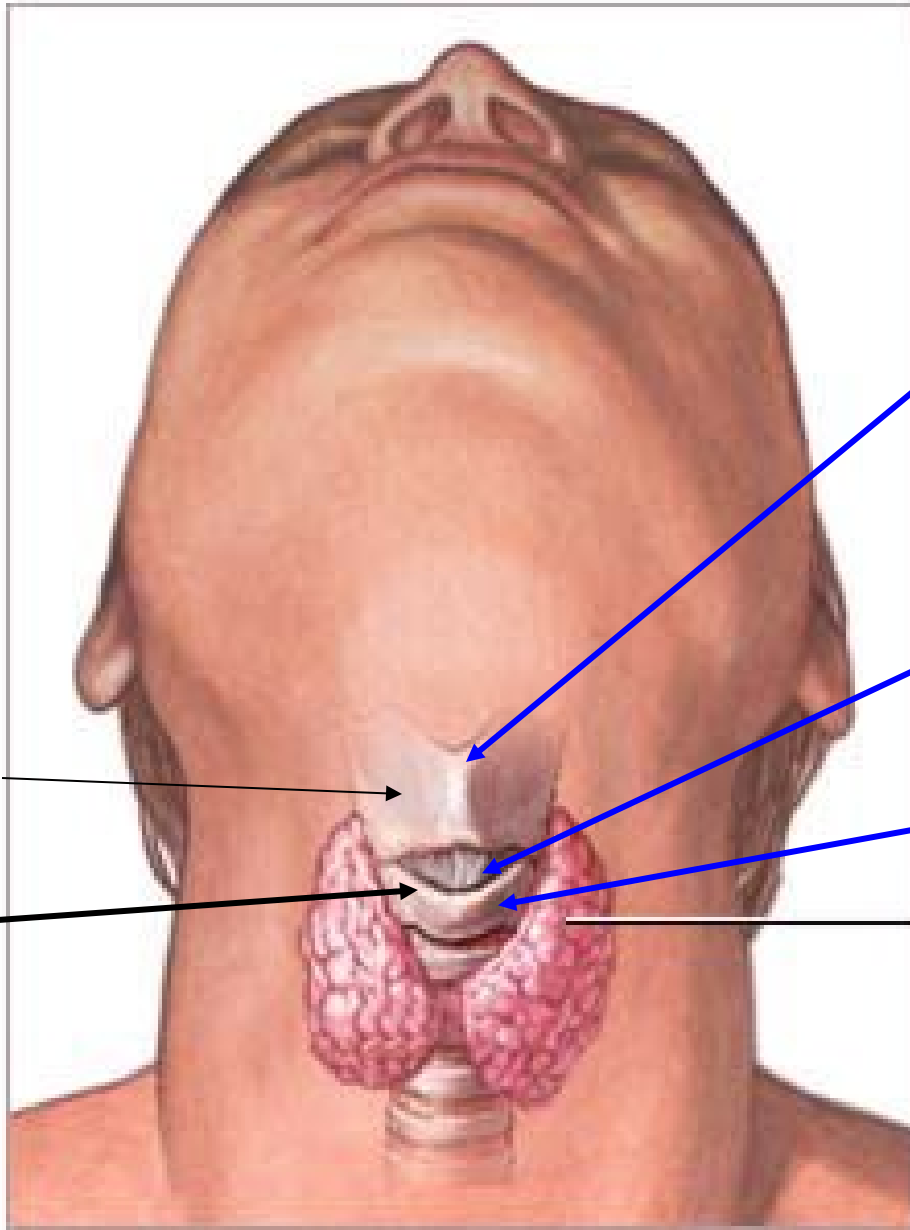
RING  
BELOW

LARYNGEAL  
PROMINENCE  
(ADAM'S APPLE)  
OF THYROID  
CARTILAGE

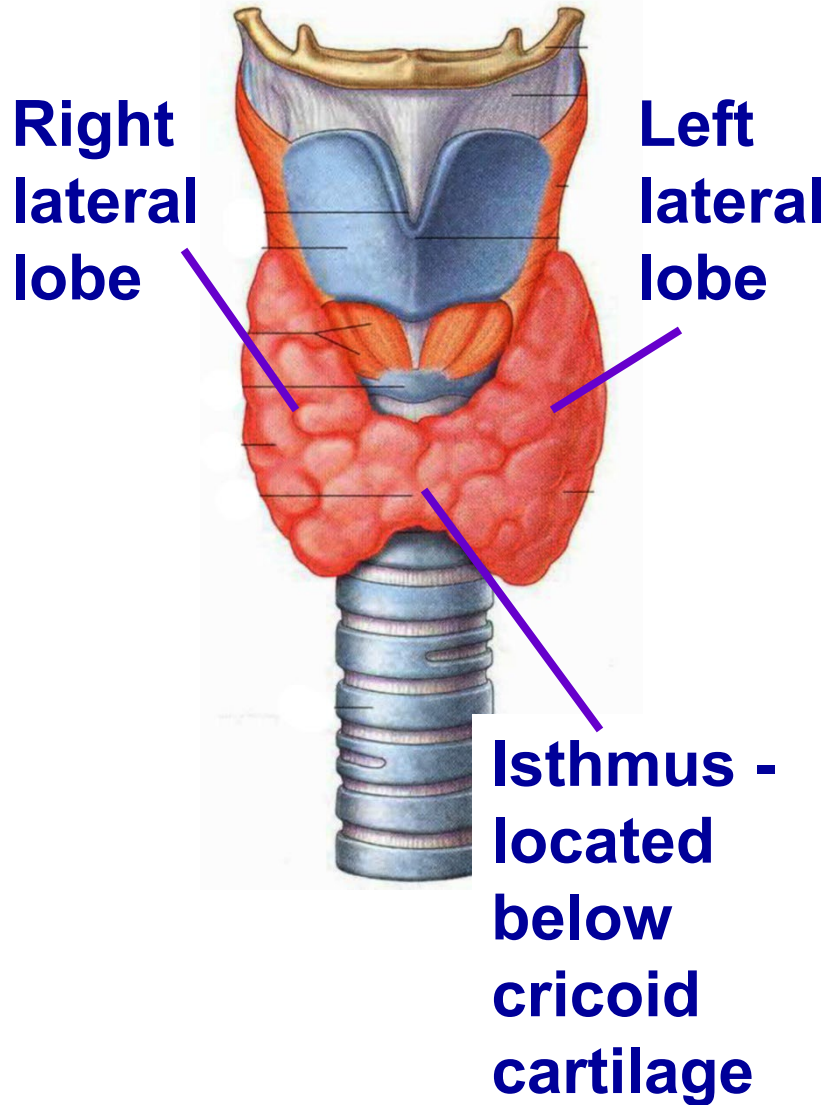
CRICO-THYROID  
MEMBRANE

CRICOID  
CARTILAGE

Thyroid gland

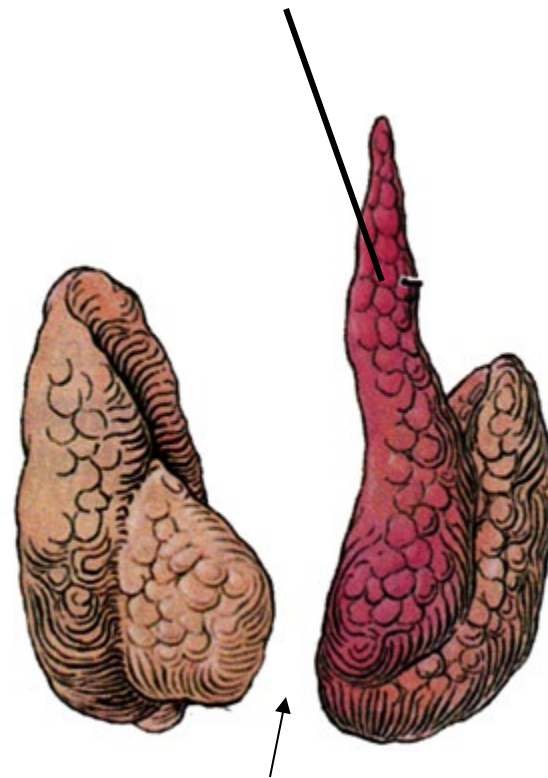


# THYROID GLAND



## Normal variations common

**Pyramidal lobe - close to midline along pathway of embryonic Thyroglossal duct**



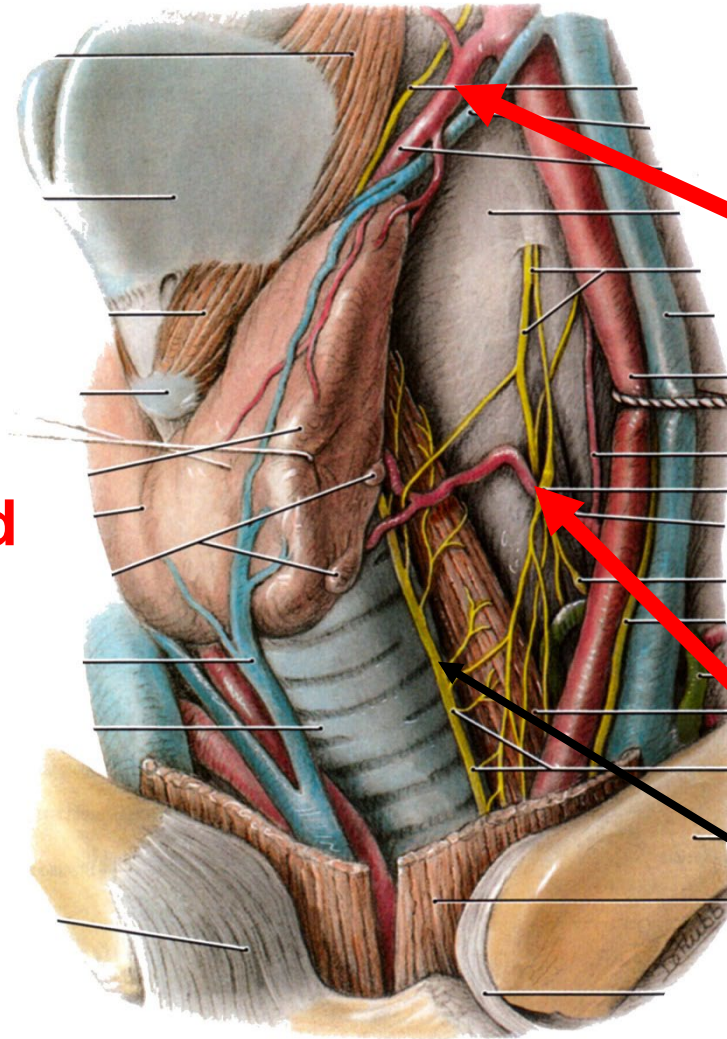
**Absence of Isthmus**

# THYROID GLAND - ARTERIAL/ nerve SUPPLY

Nose



**Very vascular-arteries accompanied by nerves**



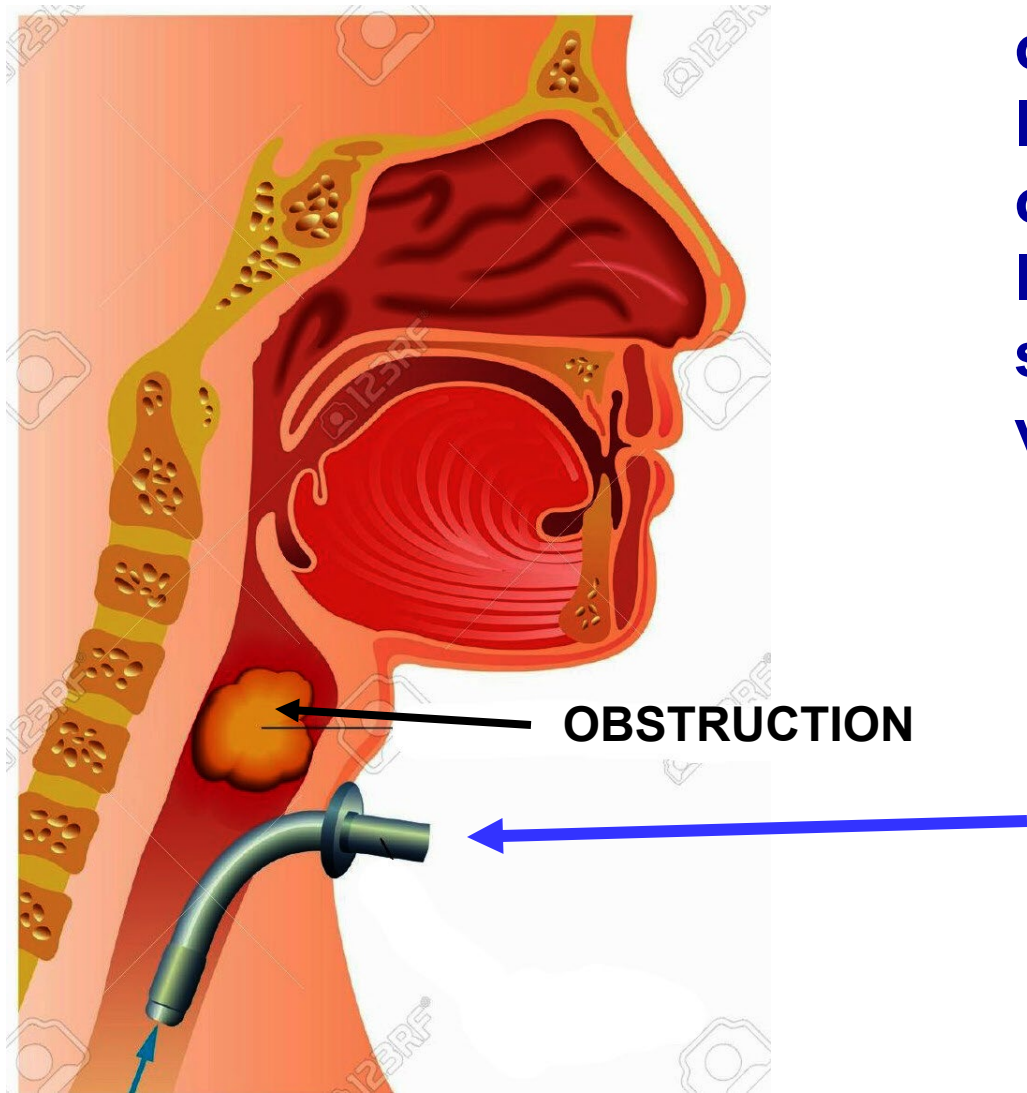
**FROM EXT. CAROTID**

**a) Sup. Thyroid artery (courses with Sup. Laryngeal n. from X)**

**b) Inf. Thyroid artery (courses with Recurrent Laryngeal n. from X)**

**Clinical: In thyroid surgery care taken not to damage Recurrent Laryngeal Nerve; paralyze all muscles of Larynx (except Cricothyroid) on one side; patient has only hoarse voice or whisper.**

# OBSTRUCTION OF LARYNX: TRACHEOTOMY



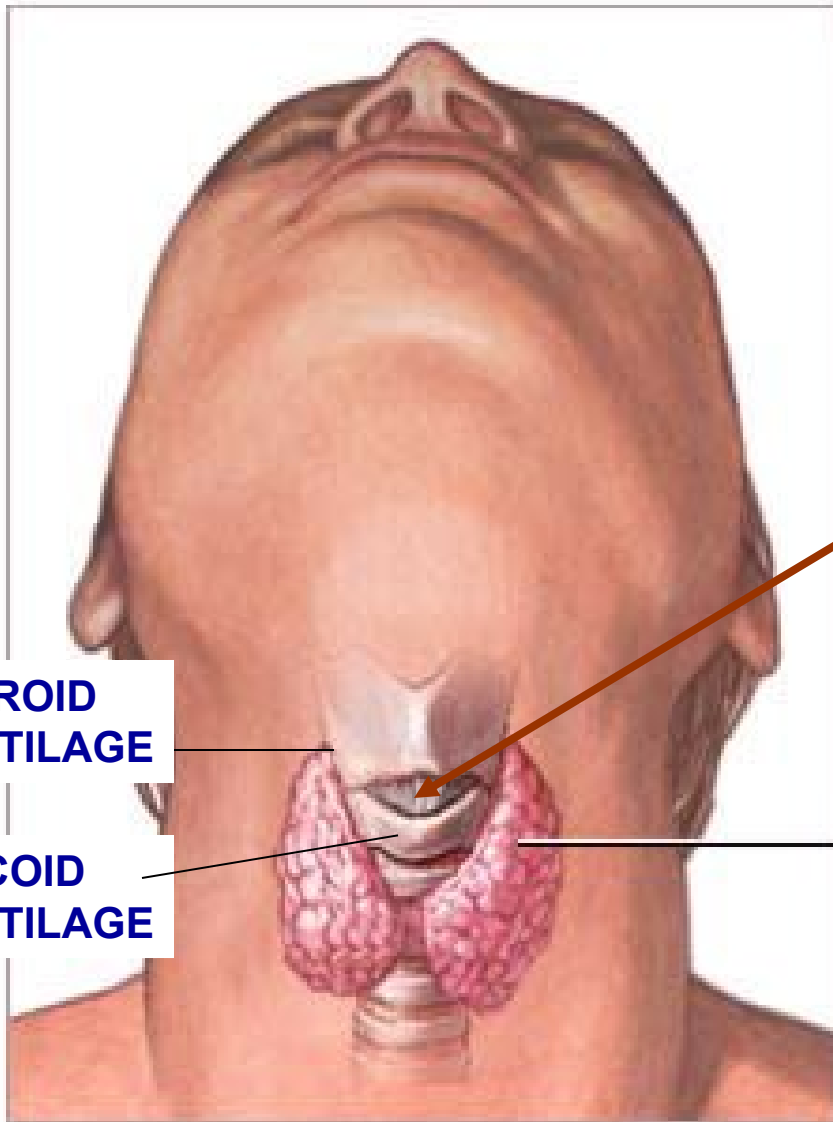
open airway to  
lungs below  
obstructed  
larynx OR  
swollen  
vestibular folds

Tracheotomy  
- cut between  
1<sup>st</sup> and 2<sup>nd</sup> or  
2<sup>nd</sup> and 3<sup>rd</sup>  
Tracheal  
cartilages



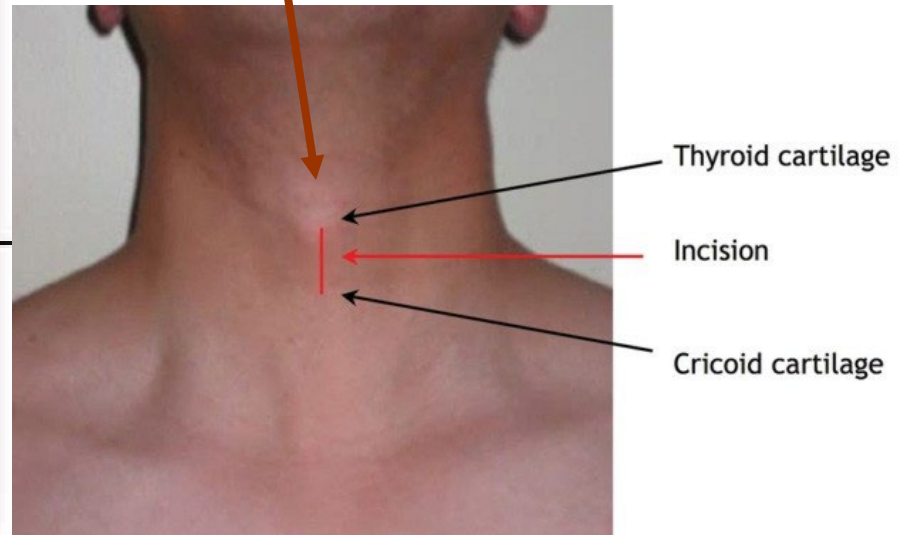
# OBSTRUCTION OF LARYNX: CRICOTHYROTOMY

**CLINICALLY IMPORTANT:**  
**IN ANAPHYLACTIC SHOCK,**  
**INSERT TUBE TO**  
**CRICOTHYROID**  
**MEMBRANE (LESS BLEEDING**  
**THAN TRACHEOTOMY)**

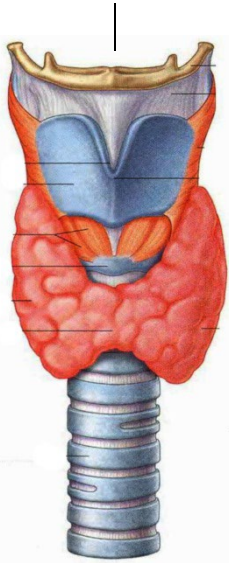


**Cricothyroid  
Membrane**

**\*\***



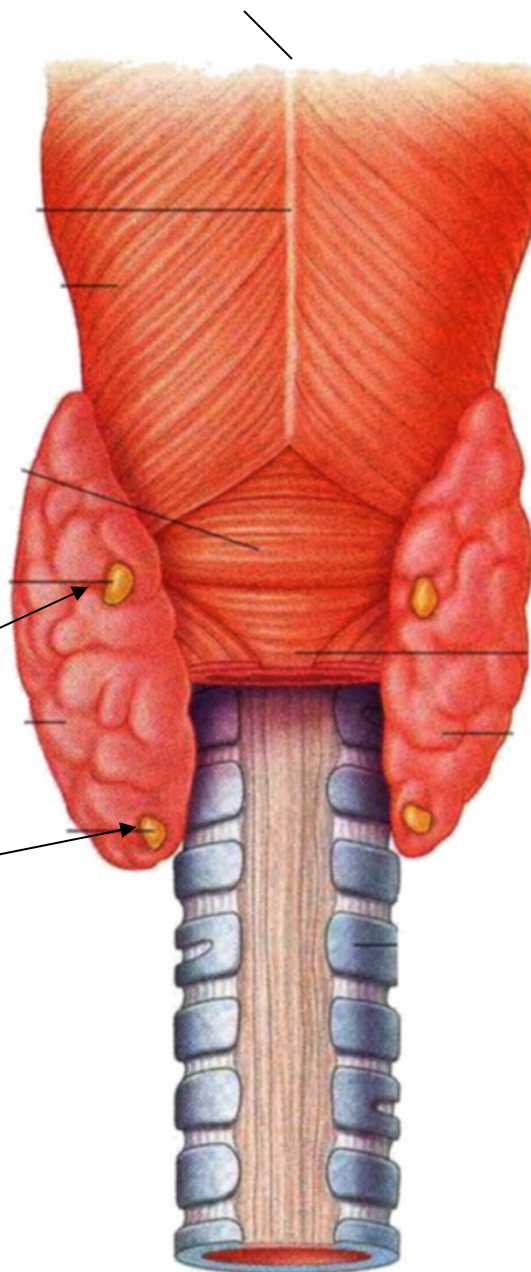
## ANT. VIEW



**Superior  
parathyroid  
gland**

**Inferior  
parathyroid  
gland**

## POSTERIOR VIEW



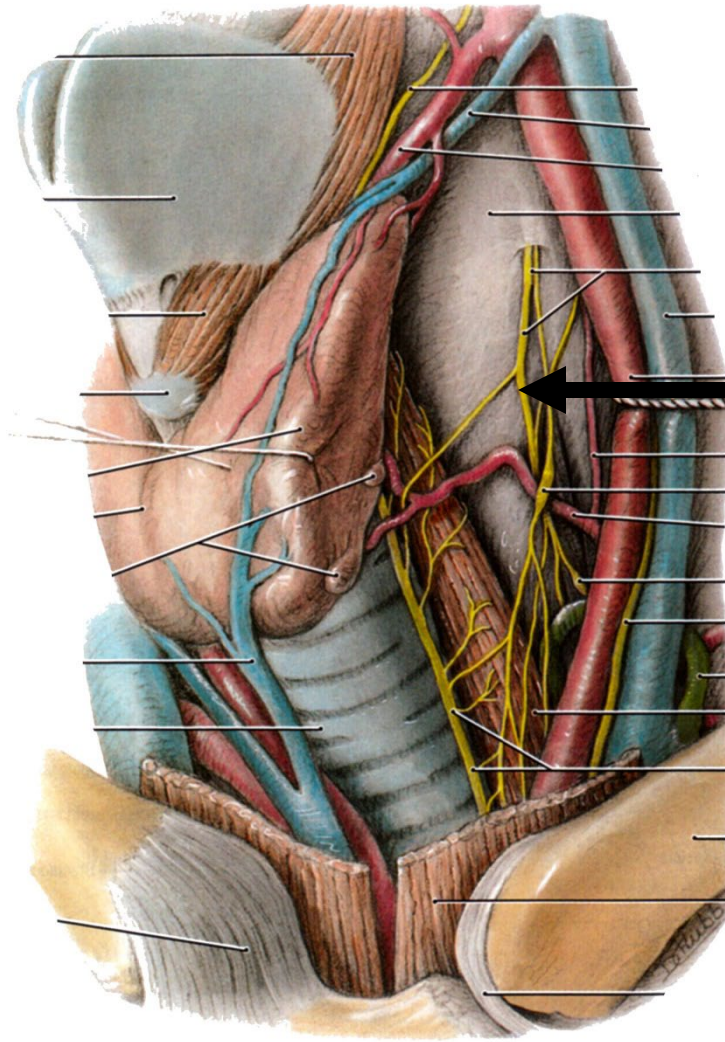
## PARATHYROID GLANDS

**- 4 small  
bodies (2  
on each  
side)  
located  
posterior  
to or  
within  
Thyroid  
gland**

Nose



# SYMPATHETIC CHAIN



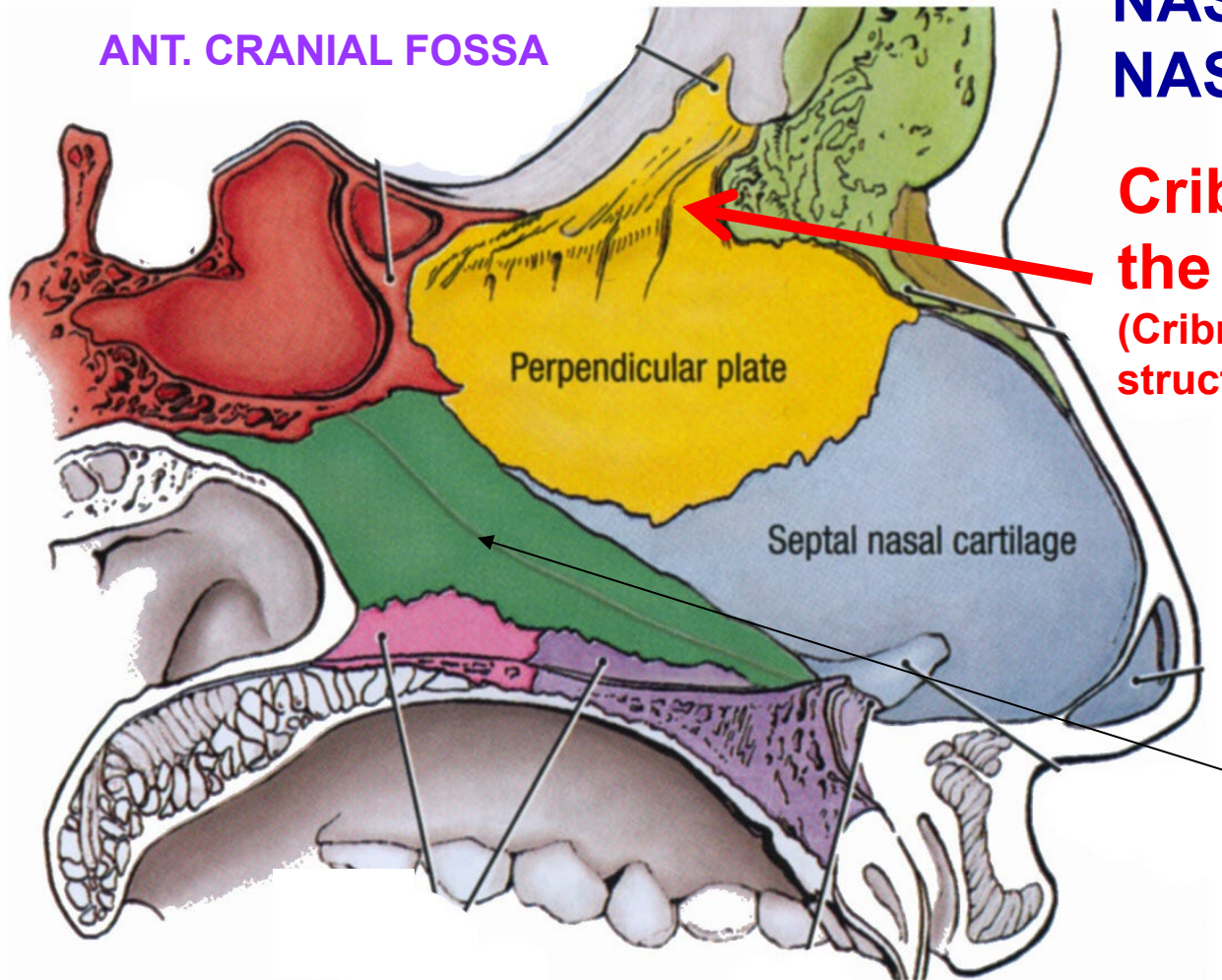
\*\*

**Sympathetic trunk- deep to (not in) Carotid Sheath**



# NASAL CAVITY, TONSILS

**MEDIAL WALL OF  
NASAL CAVITY =  
NASAL SEPTUM**



**Cribriform plate of  
the ethmoid bone  
(Cribriform; definition =  
structure with numerous holes)**

**CLINICAL – Fracture of nose can break Cribriform plate, floor of Ant. Cranial fossa - leak CSF from nose; can result in Meningitis**



# NASAL CAVITY: CONCHAE AND SPACES

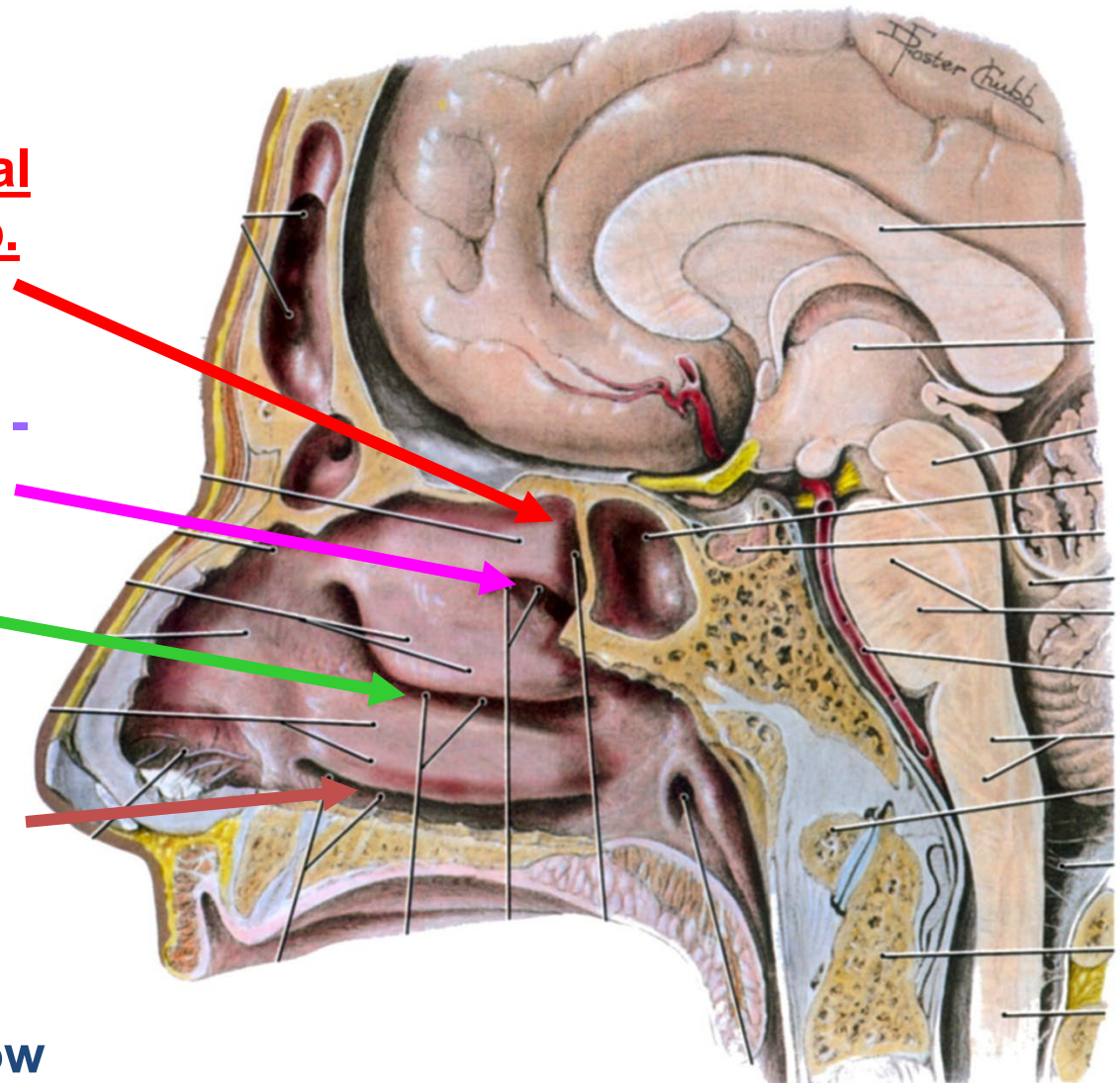
a. Spheno-Ethmoidal Recess - above Sup. Concha

b. Superior Meatus - Below Sup. Concha

c. Middle Meatus - Below Mid. Concha

d. Inferior Meatus - Below Inf. Concha

**Meatus = Passage**  
(Latin), located below  
concha



# NASAL CAVITY: OPENINGS

## a. Sphenoethmoidal Recess

- 1) Olfactory Foramina
- 2) Sphenoid air sinus

## b. Superior Meatus – Post. Ethmoidal air cells

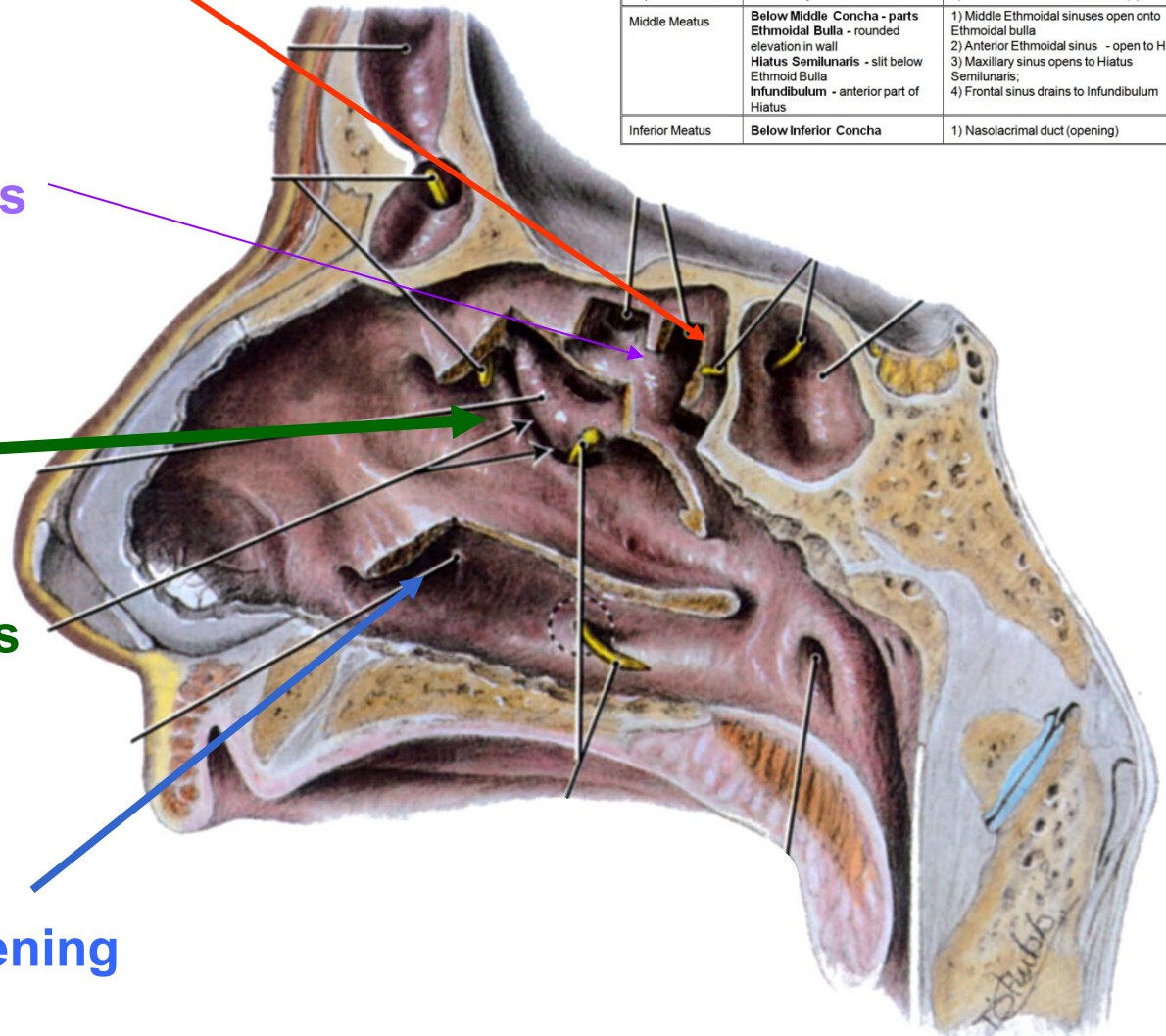
## c. Middle Meatus

- 1) Middle ethmoidal air cells - Bulla
- 2) Ant. Ethmoidal air cells - Hiatus Sem.
- 3) Max. Sinus - Hiatus Semilunaris
- 4) Frontal Sinus - Infundibulum.

## d. Inferior Meatus – opening of Nasolacrimal duct

### SUMMARY CHART IN HANDOUT

Space	Location	Openings/Sinuses
Sphenoethmoidal Recess	Above Superior Concha	1) Olfactory foramina of cribriform plate and 2) Sphenoidal air sinus (opening)
Superior Meatus	Below Superior Concha	1) Posterior Ethmoidal Air sinus (opening)
Middle Meatus	Below Middle Concha - parts Ethmoidal Bulla - rounded elevation in wall Hiatus Semilunaris - slit below Ethmoid Bulla Infundibulum - anterior part of Hiatus	1) Middle Ethmoidal sinuses open onto Ethmoidal bulla 2) Anterior Ethmoidal sinus - open to Hiatus Semilunaris; 3) Maxillary sinus opens to Hiatus Semilunaris; 4) Frontal sinus drains to Infundibulum
Inferior Meatus	Below Inferior Concha	1) Nasolacrimal duct (opening)





# NERVES of NASAL CAVITY

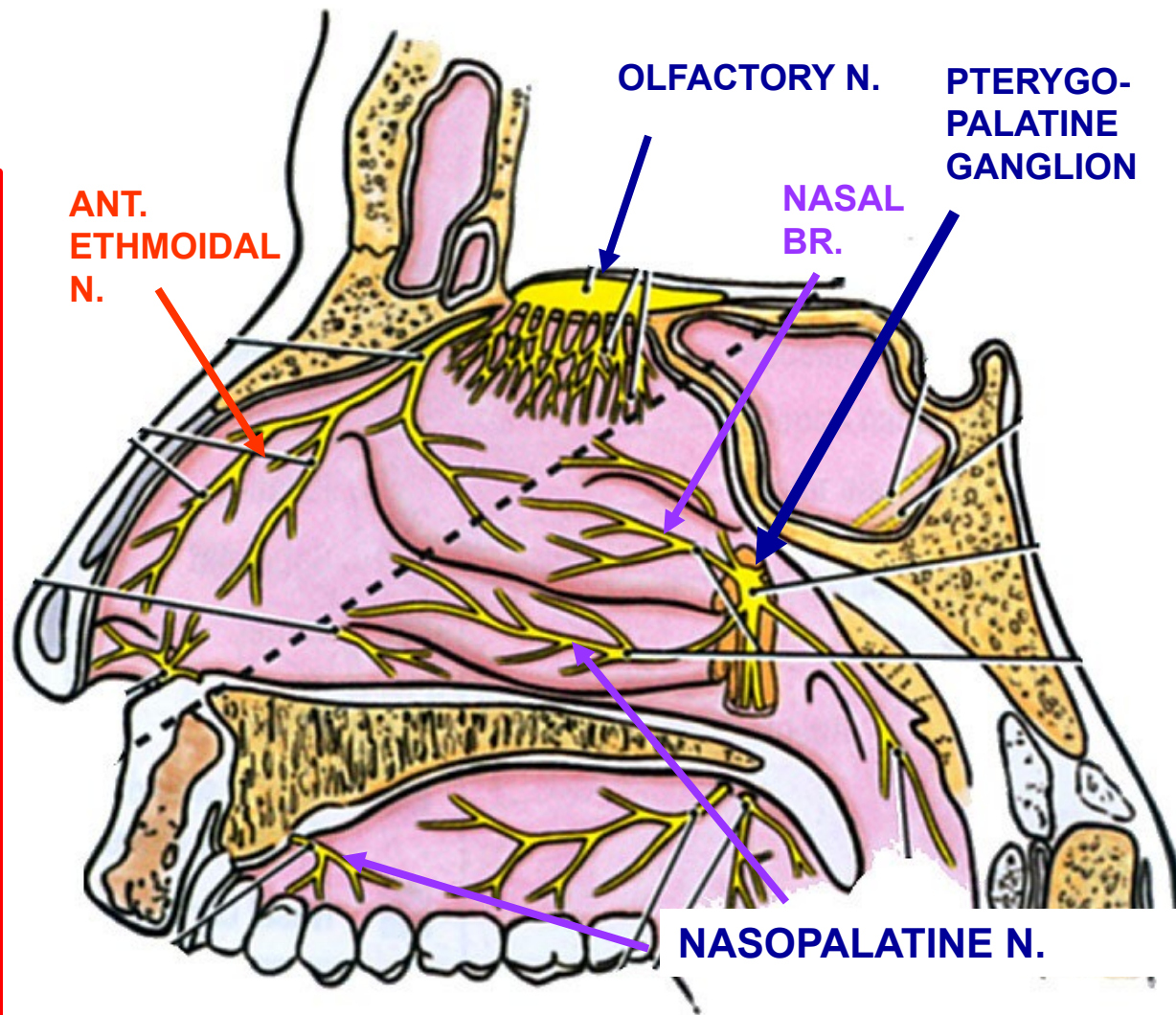
## Nerves

1. Olfactory N. -  
SMELL Olfactory  
Area

2. General Sensation -  
**ALL SOMATIC  
SENSORY** touch,  
pain, etc. \*

**V1 + V2**

Mucous Glands of  
nose - VISCERAL  
MOTOR PARASYMP. -  
VII - Facial N. by  
Pterygopalatine  
Ganglion \*

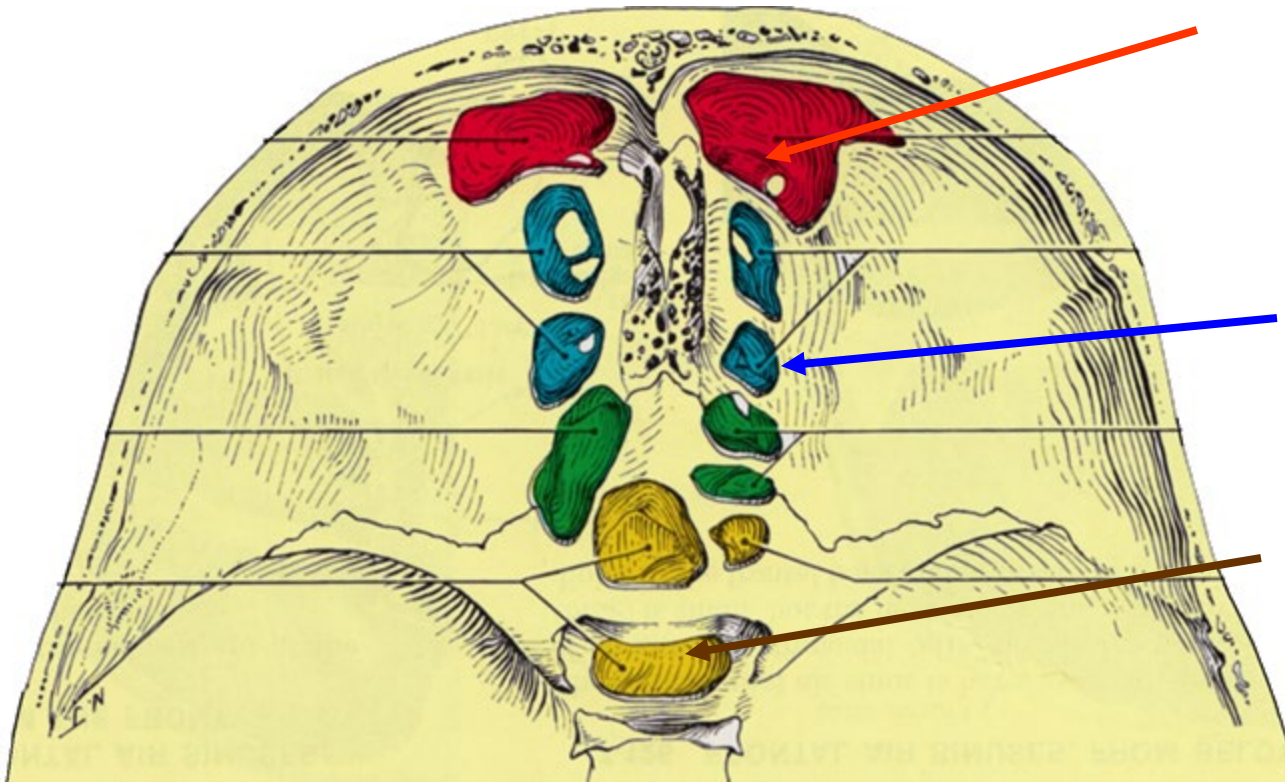


# PARANASAL AIR SINUSES

VIEW: FLOOR OF  
ANT. CRAN. FOSSA  
WITH BONE  
REMOVED

All usually paired, **NAMED FOR BONES**

NOSE



A. Frontal - separate by septum, variable size

C. Ethmoid - also called air cells (Ant., Mid., Post.)

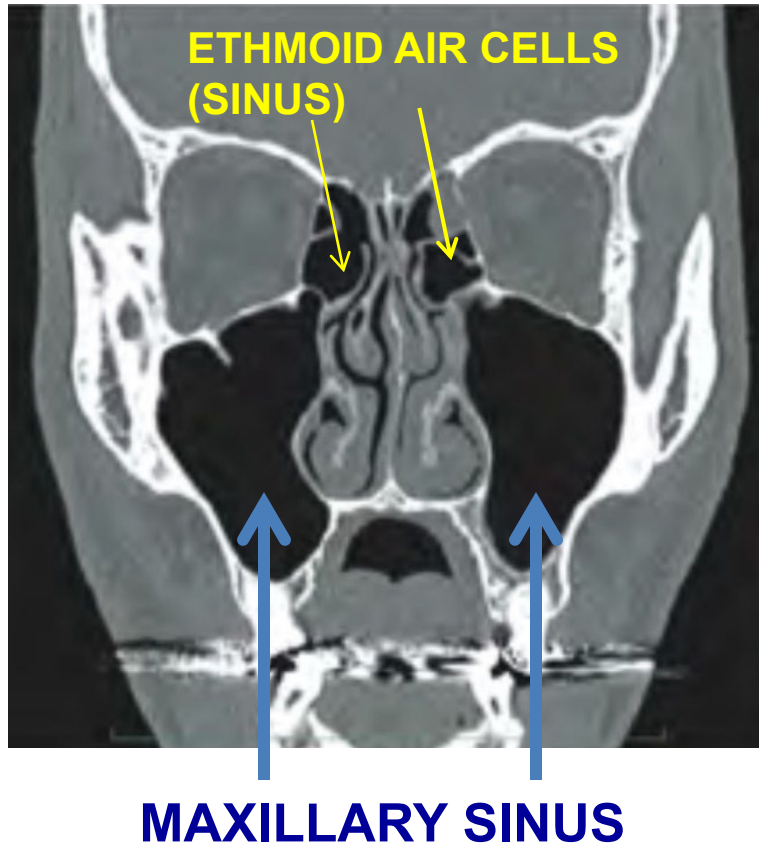
B. Sphenoid - in body of Sphenoid bone

**Ethmoid - Blocked Sinus Infection Can Spread to Orbit**

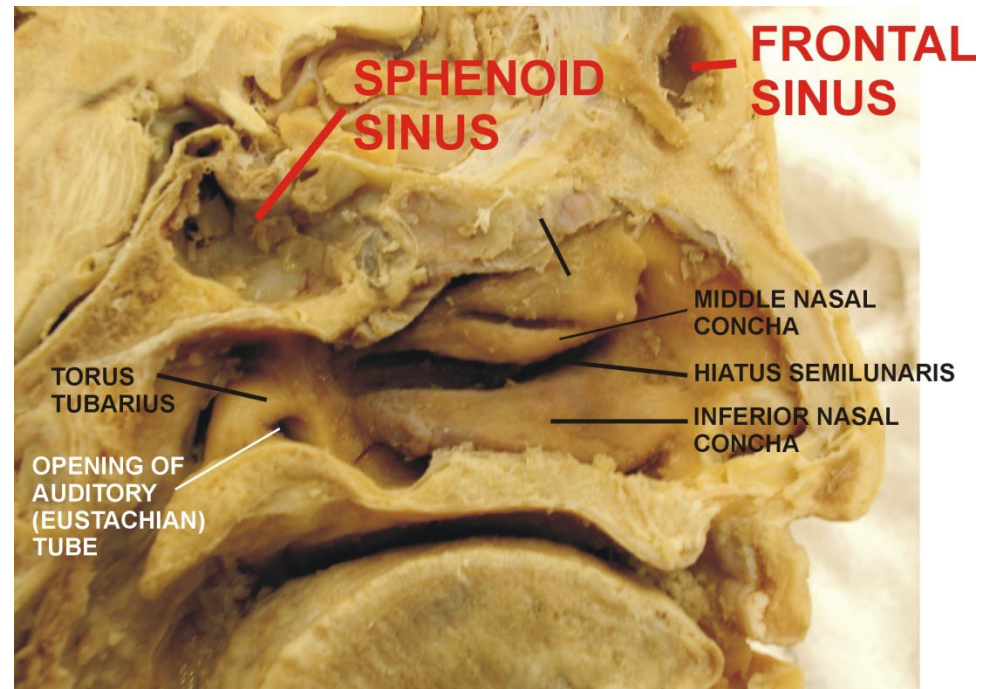


# SINUSES ON CT AND PROSECTION PICTURES

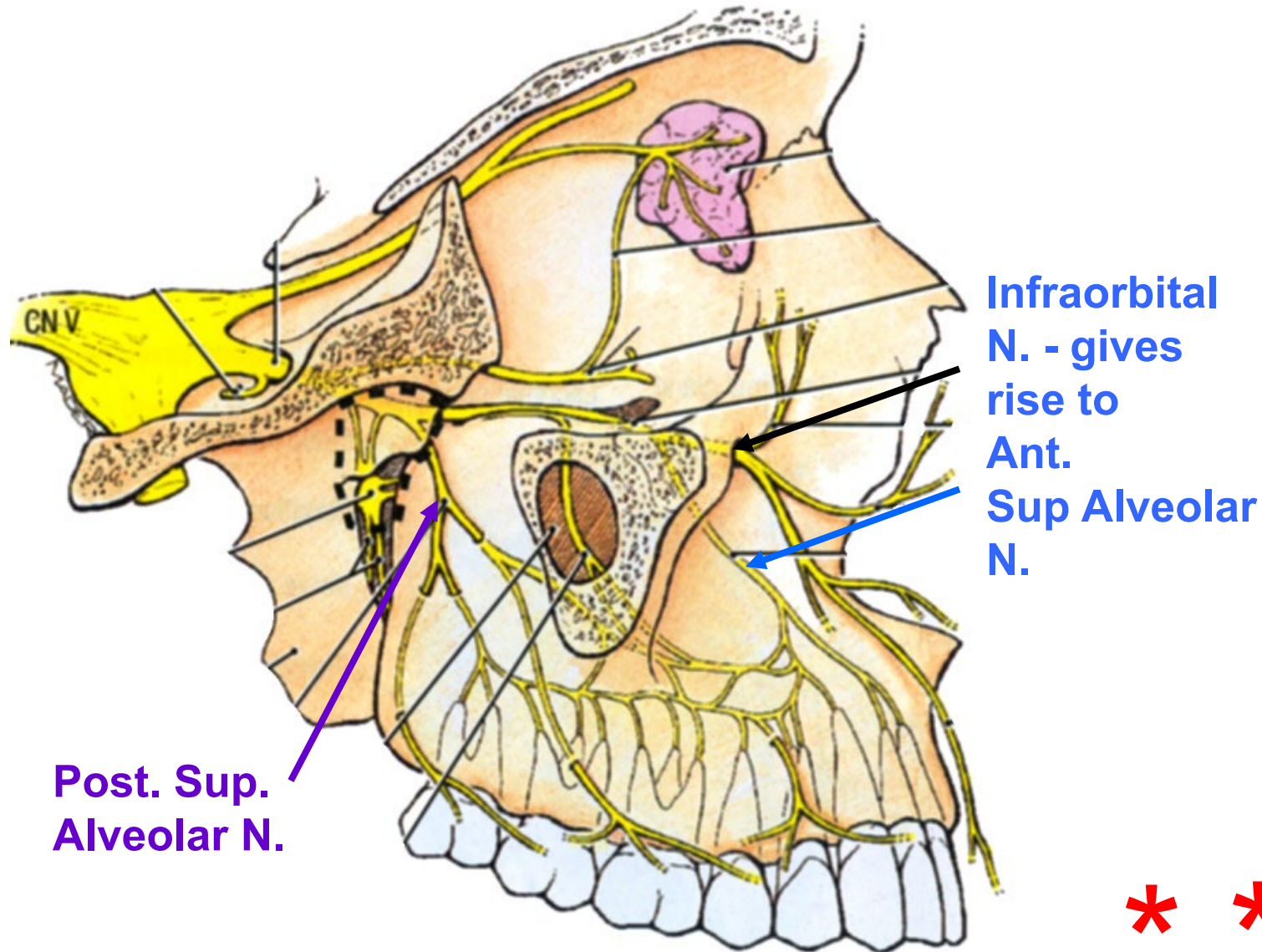
## CT IN CORONAL PLANE



## PROSECTION 75 – NASAL CAVITY



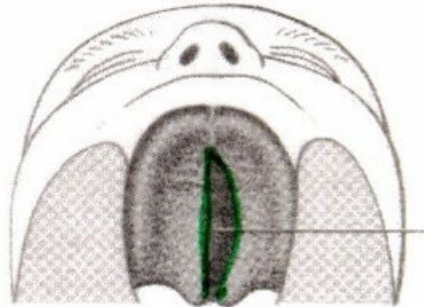
# PARANASAL AIR SINUSES: NERVES



**V2 - Ant. & Post. Sup. Alveolar N. supply Max Sinus & Teeth;  
(Infected MAXILLARY sinus can feel like a tooth ache)**

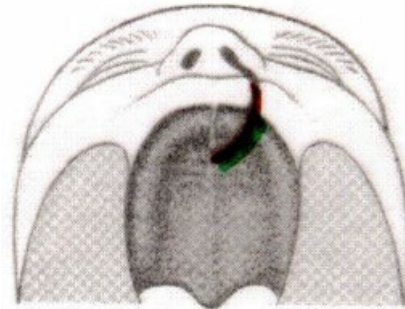
# MALFORMATIONS: CLEFT PALATE

2) Posterior Cleft Palate - Not fuse **\***  
Secondary palate  
(not fuse Maxillary Processes each side)



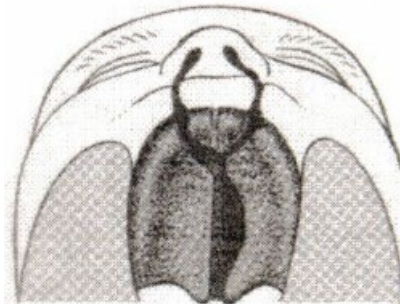
1:2500  
births

1) Anterior Cleft Palate - Not fuse **\***  
Medial Nasal Process  
and  
Maxillary Process



1:1000  
Births

Can be unilateral  
or bilateral

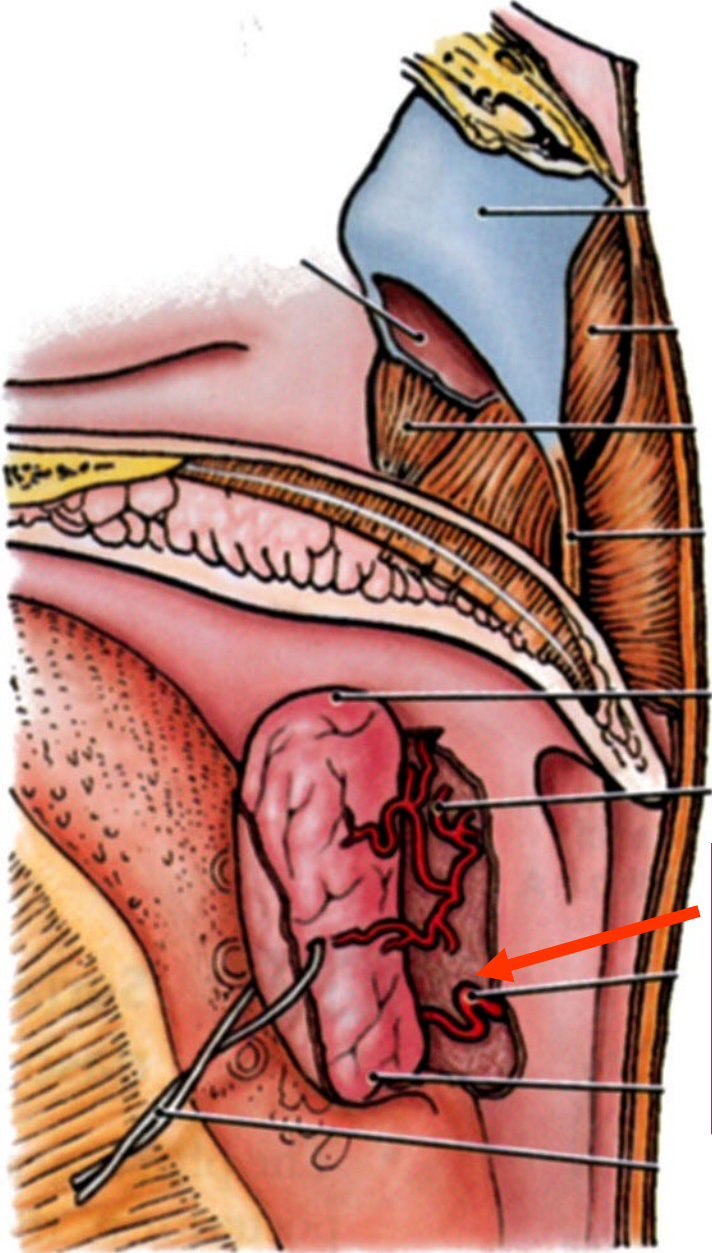
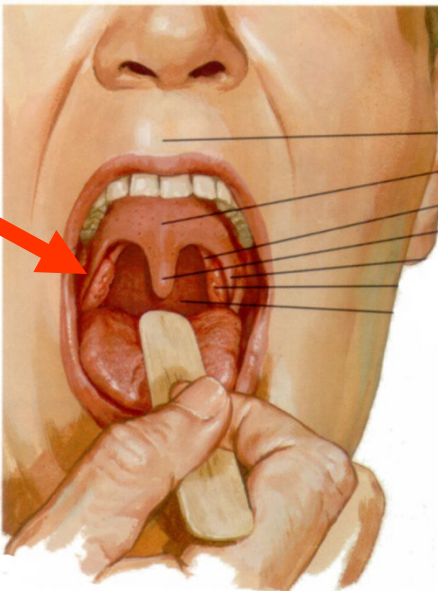


Note: Ant. Cleft Palate is same as Cleft Lip



# FACIAL ARTERY- BRANCHES MEDIAL TO MANDIBLE

PALATINE TONSIL



**NOTE: TONSILLECTOMY -  
Post-operative bleeding  
of Tonsillar branch of  
Facial artery is \* \*  
complication of  
removal of palatine  
tonsils; also damage IX**

**b) TONSILLAR  
BRANCH -  
PALATINE  
TONSIL**

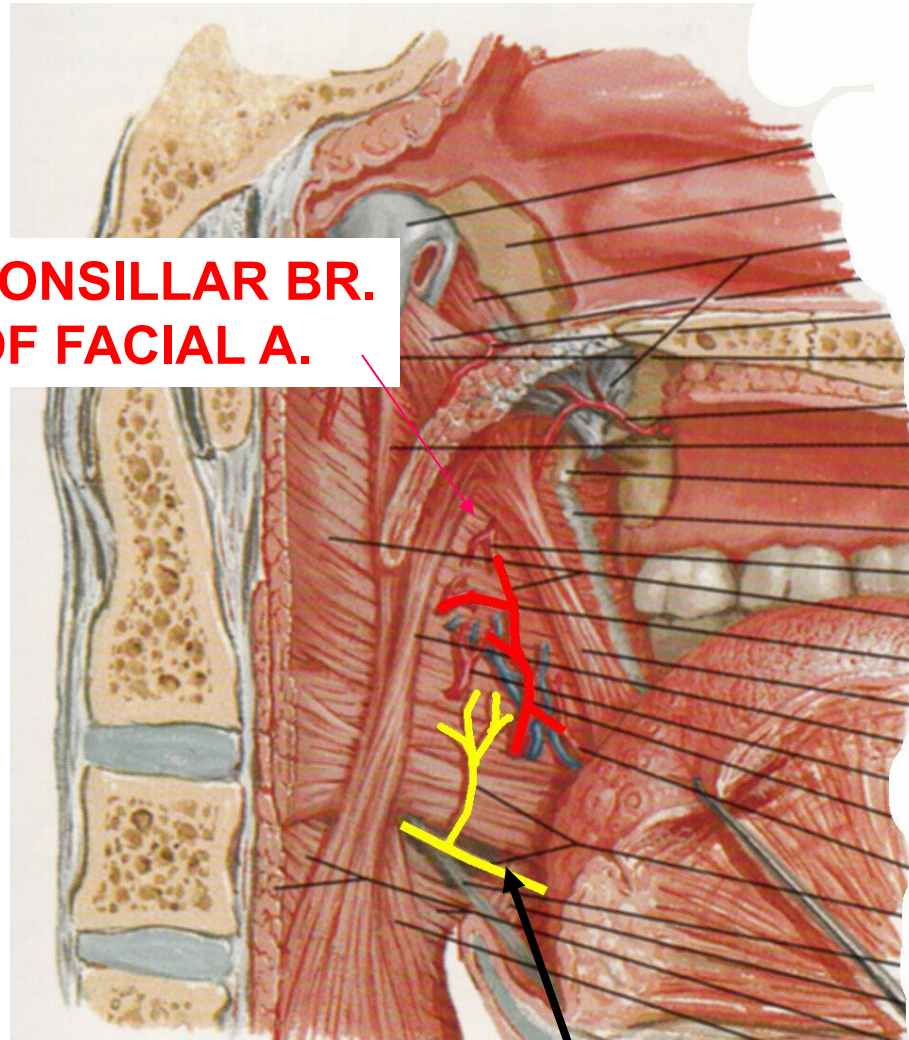


## PALATINE TONSILS

### Arteries-

From Tonsillar branch of Facial Artery - can be large  
Extensive bleeding after tonsillectomy

**TONSILLAR BR.  
OF FACIAL A.**



**Note:**

1) Glossopharyngeal Nerve  
only covered by Fascia; can  
be damaged in tonsillectomy

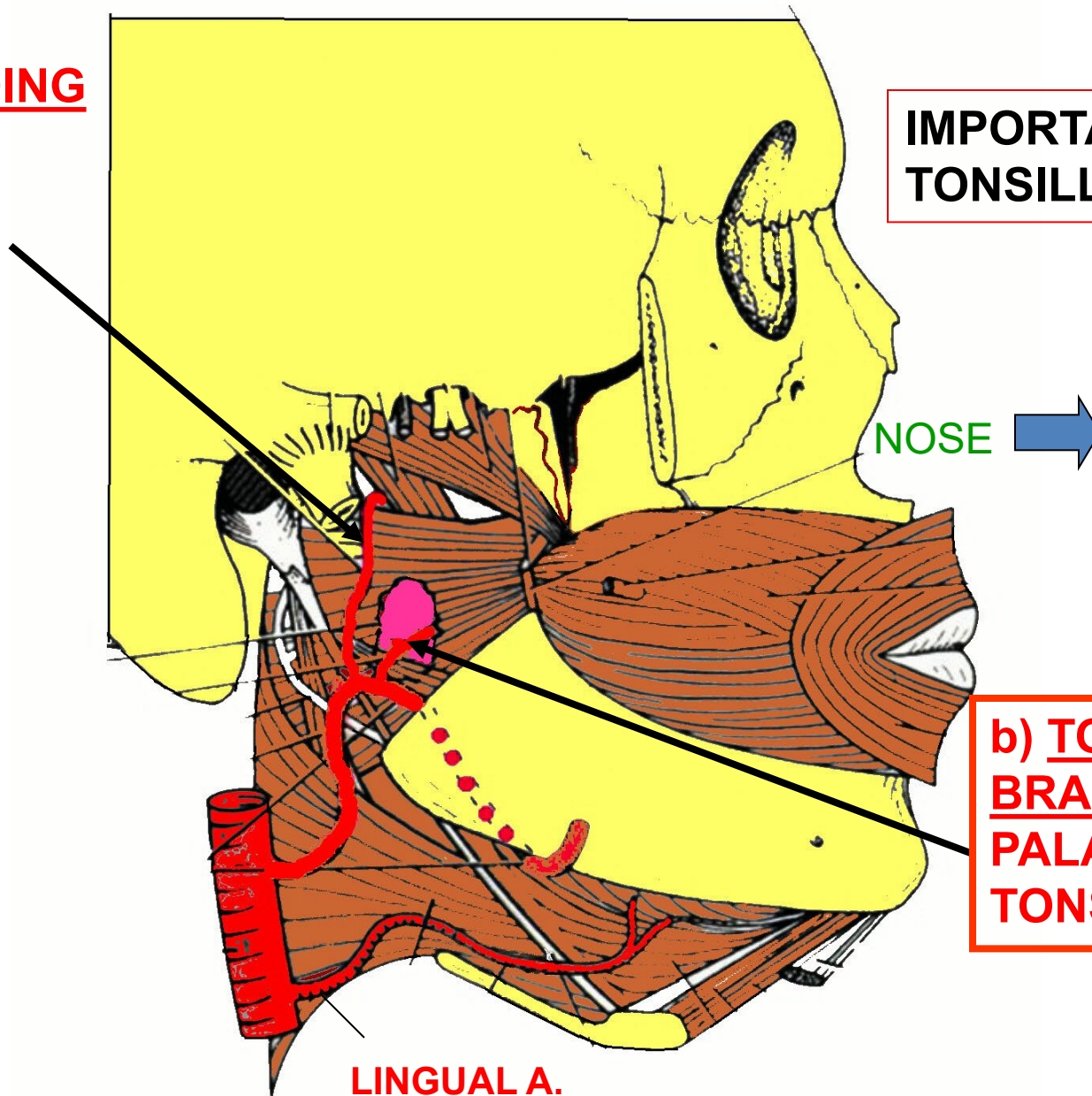
**TONSILLECTOMY**

**DAMAGE: IX – GLOSSOPHARYNGEAL NERVE**

# FACIAL ARTERY- BRANCHES MEDIAL TO MANDIBLE

a) ASCENDING PALATINE ARTERY - PALATE

IMPORTANT IN TONSILLECTOMY



NOSE →

b) TONSILLAR BRANCH - PALATINE TONSIL

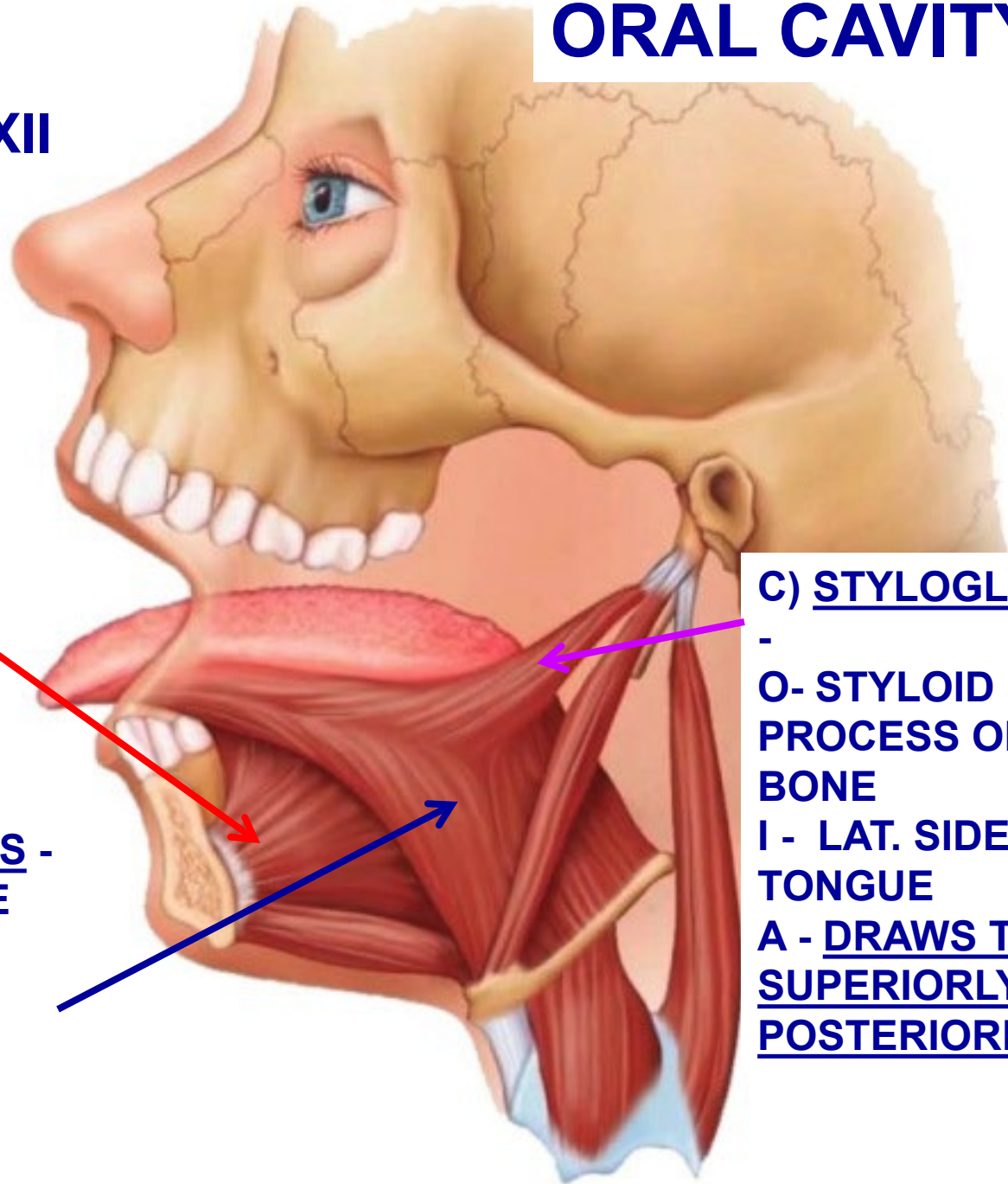
LINGUAL A.

**MUSCLES OF TONGUE - all innervated by XII**

A) **GENIOGLOSSUS**  
O - MANDIBLE  
I - TONGUE TO ITS DORSAL SURFACE  
A - **PROTRUDE**

B) **HYOGLOSSUS** -  
O - HYOID BONE  
I - LAT. SIDE OF TONGUE  
A - **DEPRESS**

**ORAL CAVITY**

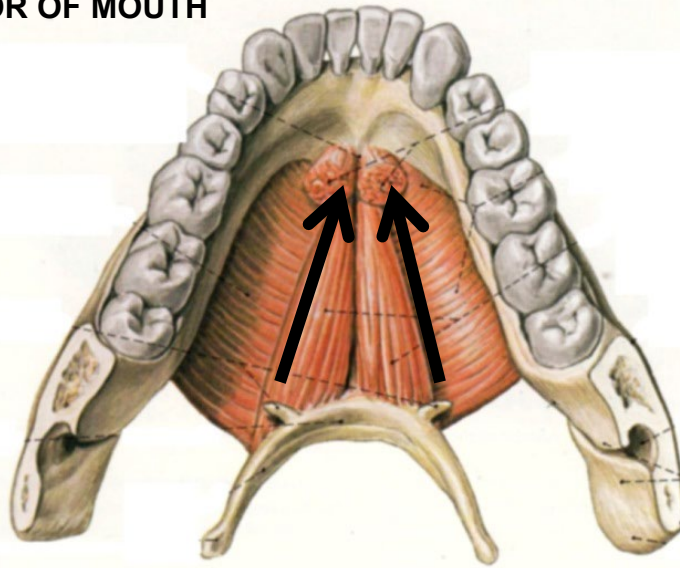


C) **STYLOGLOSSUS**  
-  
O - STYLOID PROCESS OF TEMP. BONE  
I - LAT. SIDE OF TONGUE  
A - **DRAWS TONGUE SUPERIORLY and POSTERIORLY**



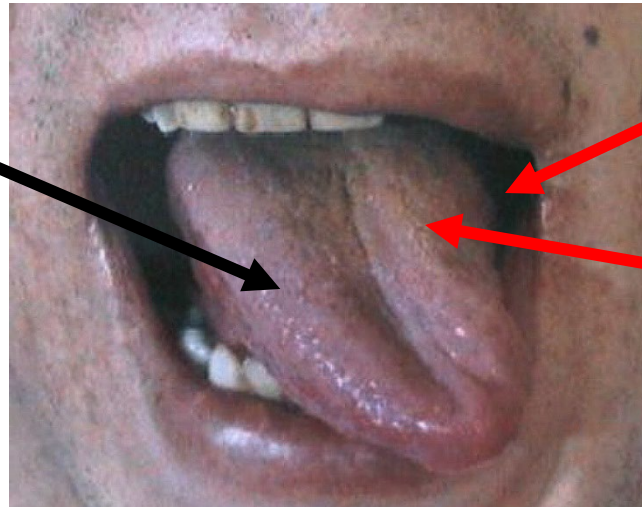VIEW OF FLOOR OF MOUTH

**GENIO-  
GLOSSUS  
DIRECTION  
OF  
ACTION**



**CLINICAL SIGN OF  
DAMAGE TO  
HYPOGLOSSAL  
NERVE (XII)**

**GENIO-  
GLOSSUS  
INTACT**



**DAMAGE  
HYPOGLOSSAL  
NERVE ON ONE  
SIDE**

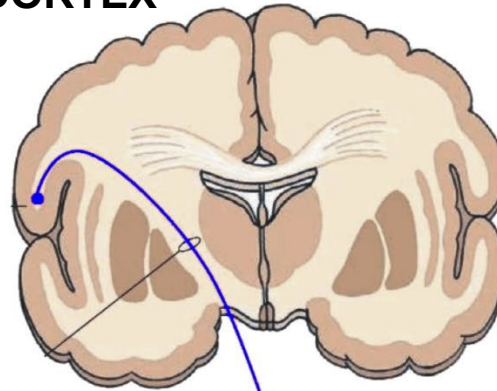
**GENIO-  
GLOSSUS  
PARALYZED**

**LOWER MOTOR NEURON LESION - PROTRUDED TONGUE \*\*  
DEVIATES TOWARD SIDE OF LESION - due to unopposed action  
of the **Genioglossus** muscle.**

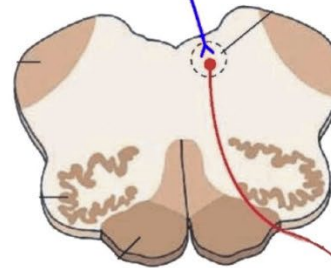


**UPPER MOTOR  
NEURON TO  
GENIOGLOSSUS -  
CONTRALATERAL**

**CORTEX**



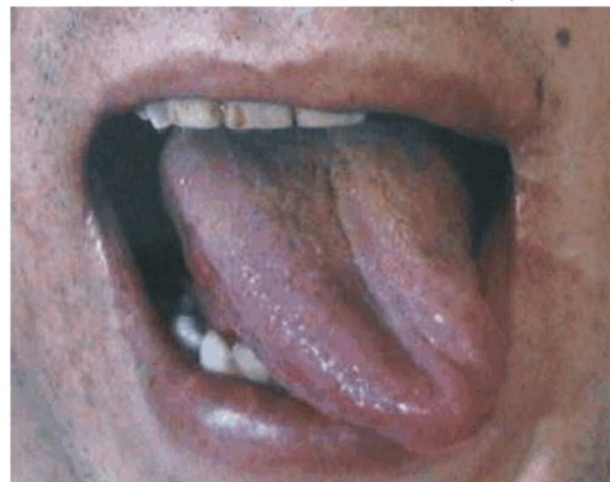**BRAINSTEM -  
MEDULLA**



**UPPER MOTOR NEURON -  
CRANIAL NERVES - ALL  
BILATERAL EXCEPT:**  
**1) ONLY CONTRALATERAL:**  
**- VII - LOWER FACE (BELOW  
ORBICULARIS OCULI)**  
**- XII - GENIOGLOSSUS**  
**- XI - TRAPEZIUS**  
**2) ONLY IPSILATERAL:**  
**- XI - STERNOCLEIDOMASTOID**

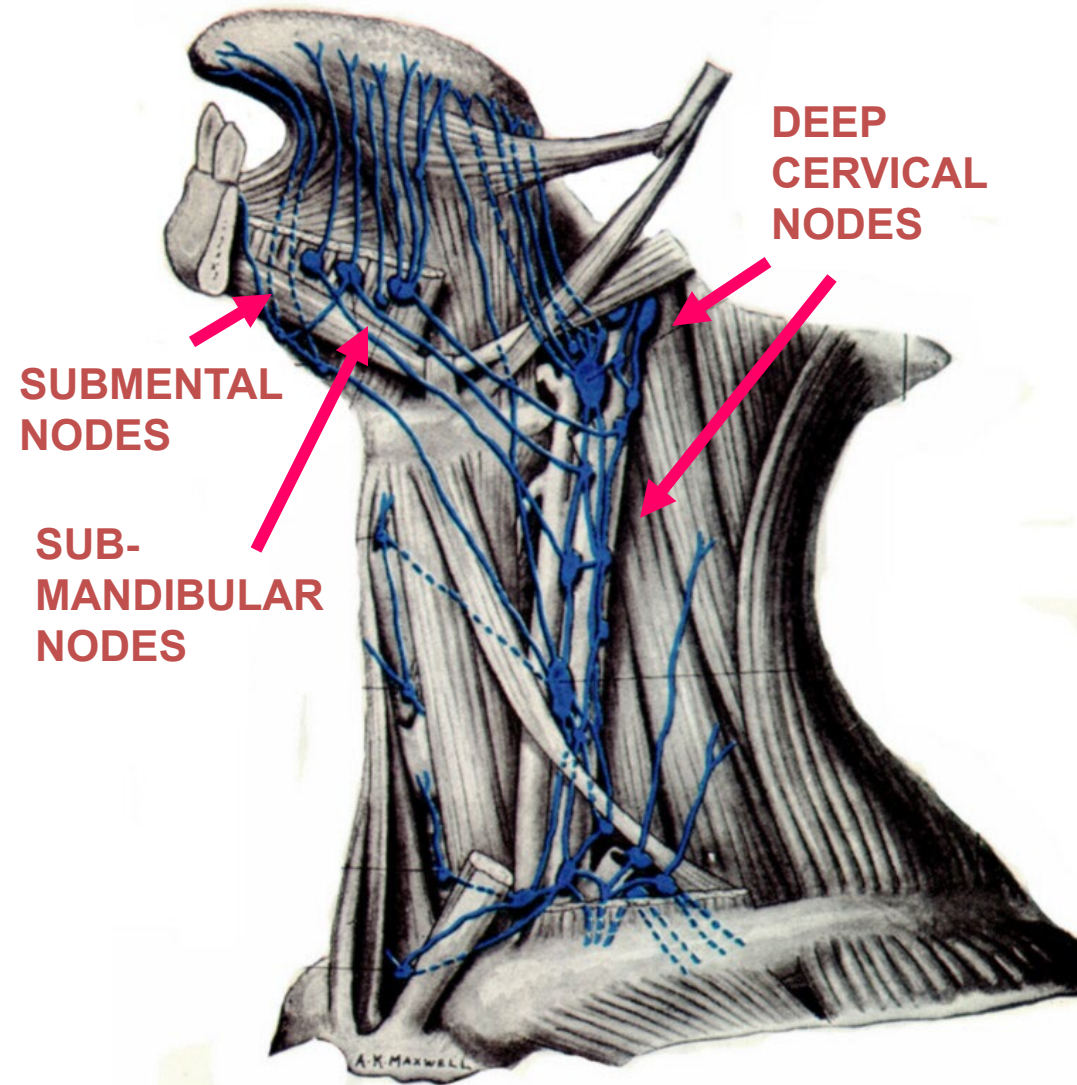
**HYPOGLOSSAL  
LOWER MOTOR  
TO GENIOGLOSSUS  
MUSCLE (IPSILATERAL)**

**DAMAGE  
UPPER MOTOR -  
TONGUE  
DEVIATES  
AWAY FROM SIDE  
OF CORTICAL  
LESION \*\*\***



**DAMAGE  
LOWER MOTOR -  
TONGUE  
DEVIATES \*\*\*  
TOWARD SIDE OF  
LOWER MOTOR  
NEURON LESION**

# LYMPHATICS OF TONGUE



1. TIP OF TONGUE to SUBMENTAL NODES
2. REST OF ANTERIOR 2/3 OF TONGUE to SUBMANDIBULAR NODES AND DEEP CERVICAL LYMPH NODES
3. POSTERIOR 1/3 OF TONGUE TO DEEP CERVICAL LYMPH NODES

**NOTE: LYMPH \*  
VESSELS OF TONGUE  
CROSS MIDLINE;  
LESION MAY SPREAD  
TO OPPOSITE SIDE**

# SENSORY INNERVATION OF TONGUE

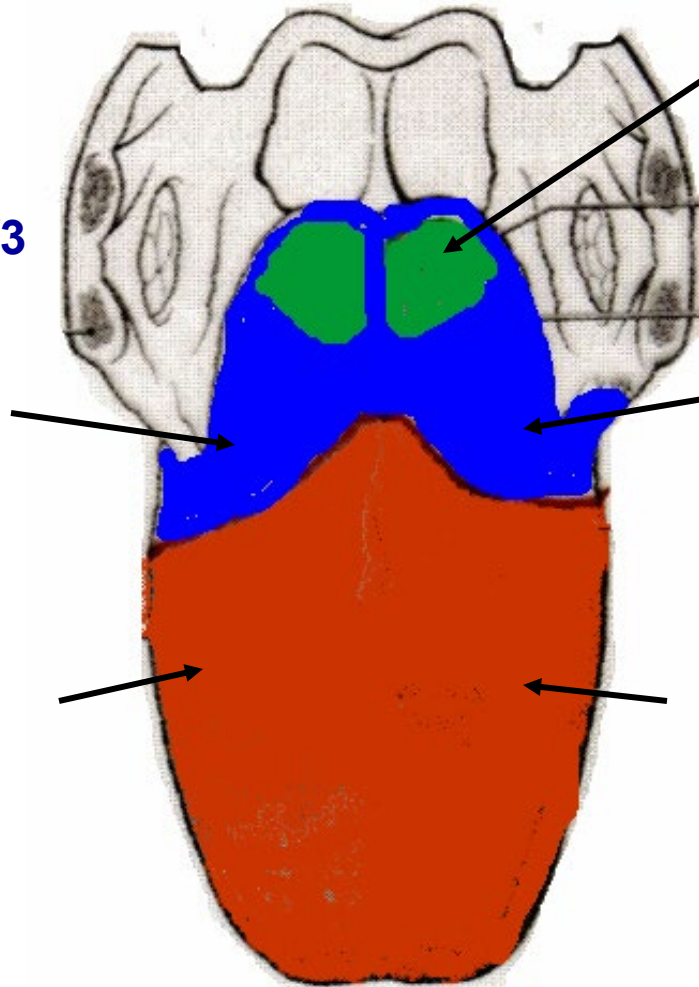
NOTE:



PHARYNGEAL PART- POST 1/3  
and ANT. TO EPIGLOTTIS-  
VISCERAL SENSORY,  
TOUCH, PAIN;  
TASTE

ORAL PART -  
ANT 2/3 -  
SOMATIC SENSORY  
TOUCH, PAIN;  
TASTE

NOTE: ALL MUSCLES INNERVATED  
BY XII HYPOGLOSSAL (SOMATIC  
MOTOR)



ANT. TO EPIGLOTTIS -  
X- VAGUS- VISCERAL  
SENSORY TOUCH AND  
TASTE

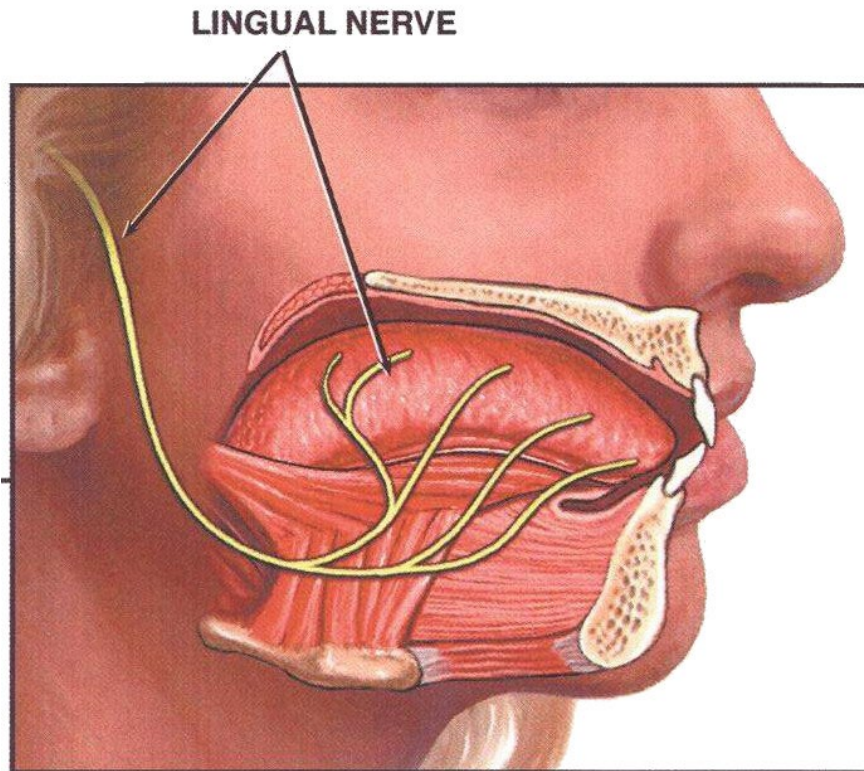
POST. 1/3 OF TONGUE  
IX -  
GLOSSOPHARYNGEA  
L - VISCERAL SENSORY TOUCH  
AND TASTE

ANT. 2/3 OF TONGUE  
1) V3 - LINGUAL N.  
SOMATIC SENSORY TOUCH  
2) VII - CHORDA TYMPANI -  
TASTE

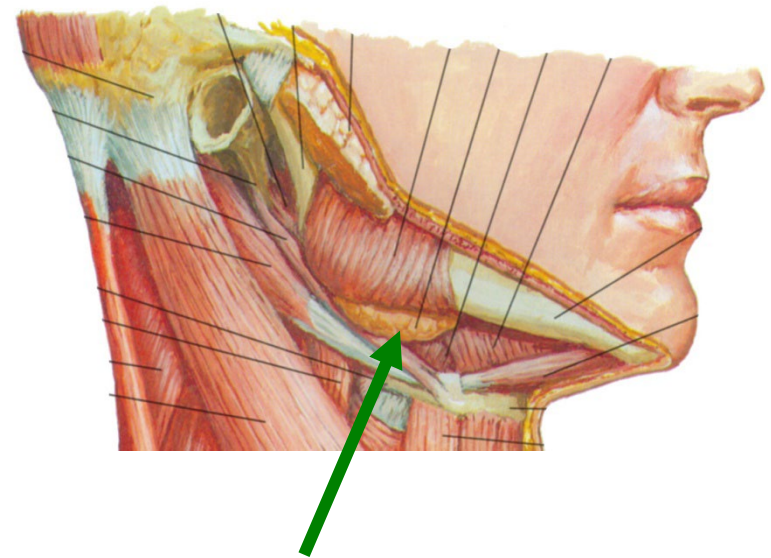


### III. PATHWAYS OF NERVES TO TONGUE

**LINGUAL NERVE (V3) - PROVIDES SOMATIC SENSATION (precise touch, etc.) to ANT. 2/3 OF TONGUE**



LATERAL VIEW OF THE TONGUE

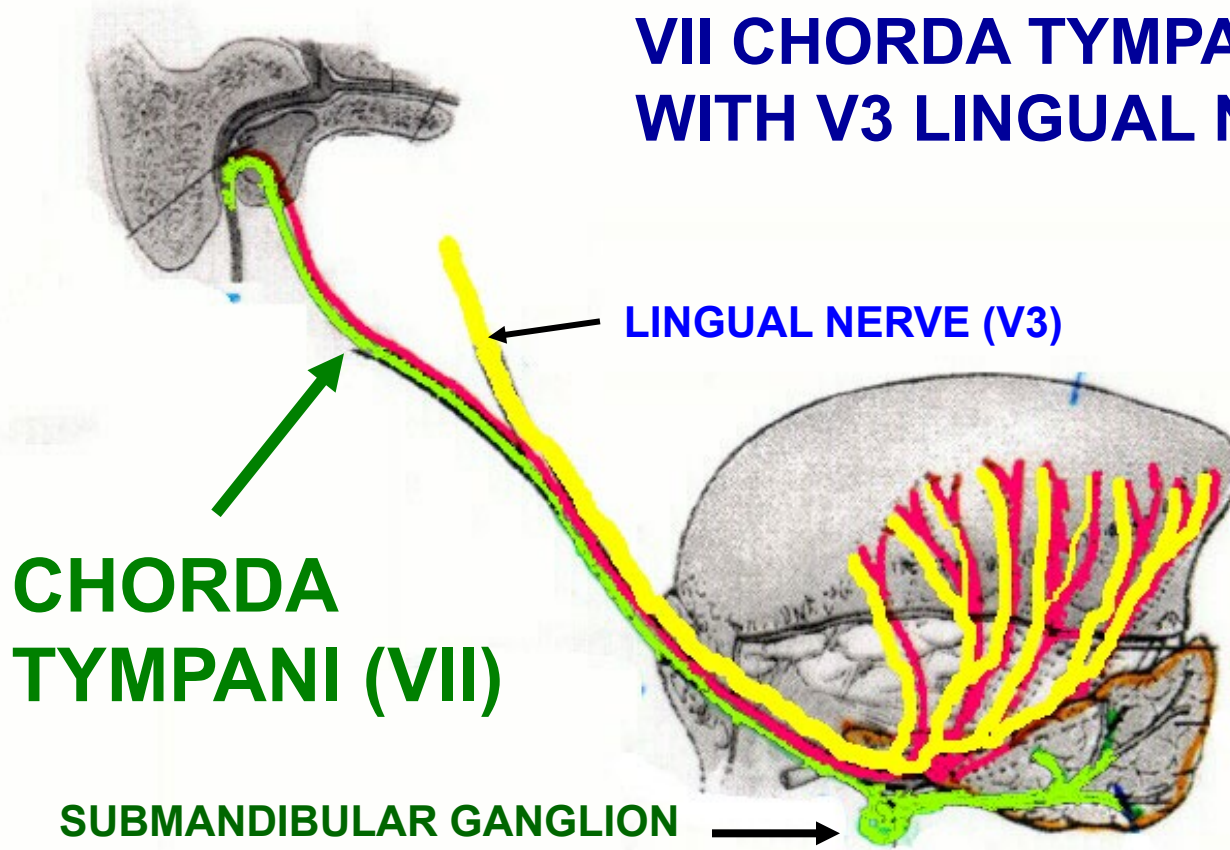


SUBMANDIBULAR SALIVARY GLAND

**LINGUAL NERVE COURSES NEAR SUBMANDIBULAR AND SUBLINGUAL SALIVARY GLANDS**



# VII CHORDA TYMPANI HITCHHIKES WITH V3 LINGUAL NERVE



**CHORDA TYMPANI (VII)**

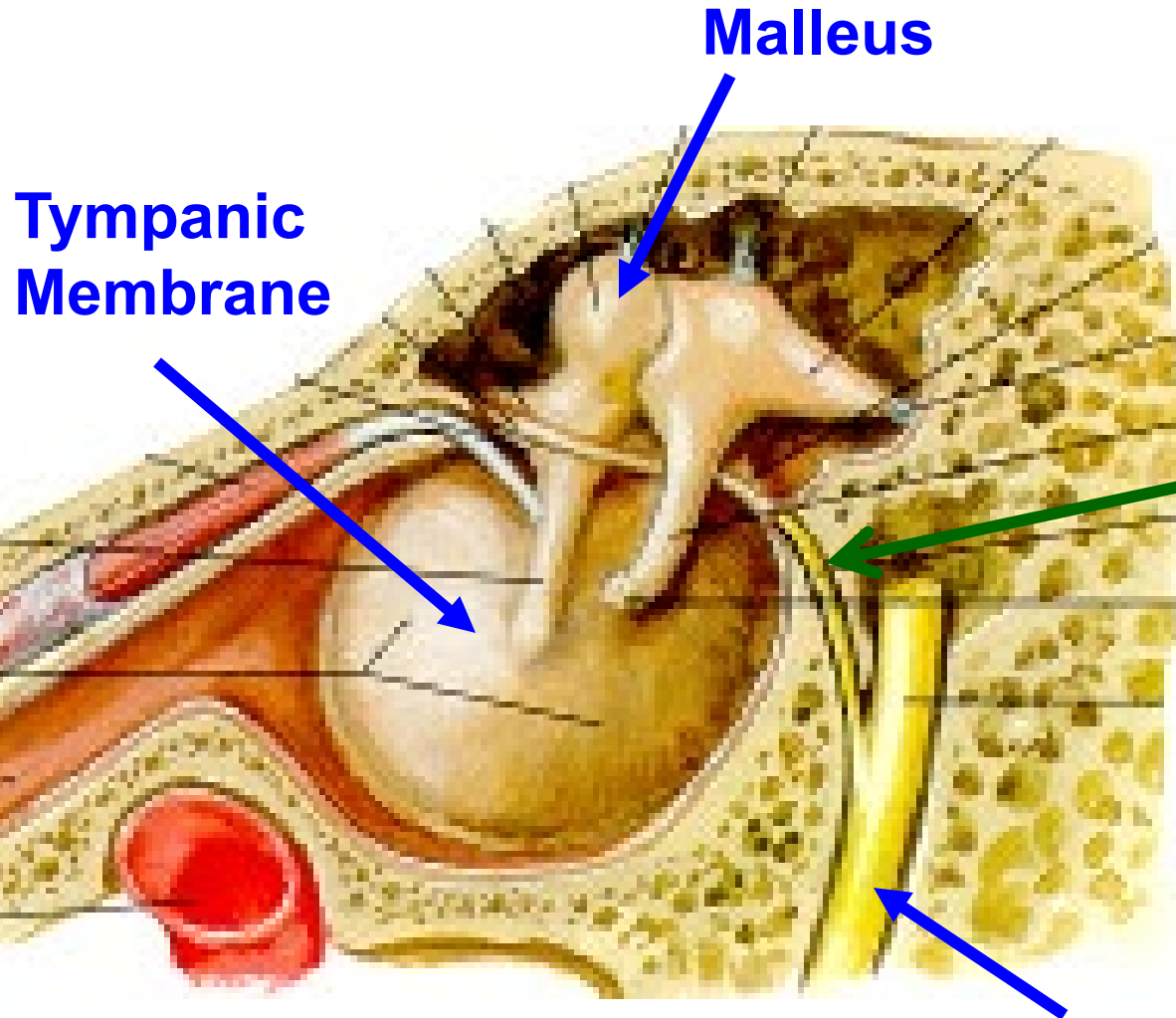
**LINGUAL NERVE (V3)**

**SUBMANDIBULAR GANGLION**

**CHORDA TYMPANI (VII)-  
Parasympathetics  
- to  
Submandibular,  
Sublingual  
salivary glands  
- Taste fibers - to  
taste buds on Ant.  
2/3 of tongue**

# CHORDA TYMPANI CROSSES TYMPANIC MEMBRANE

Taste to ant. 2/3 of tongue  
Parasympathetic to submandibular, sublingual salivary glands



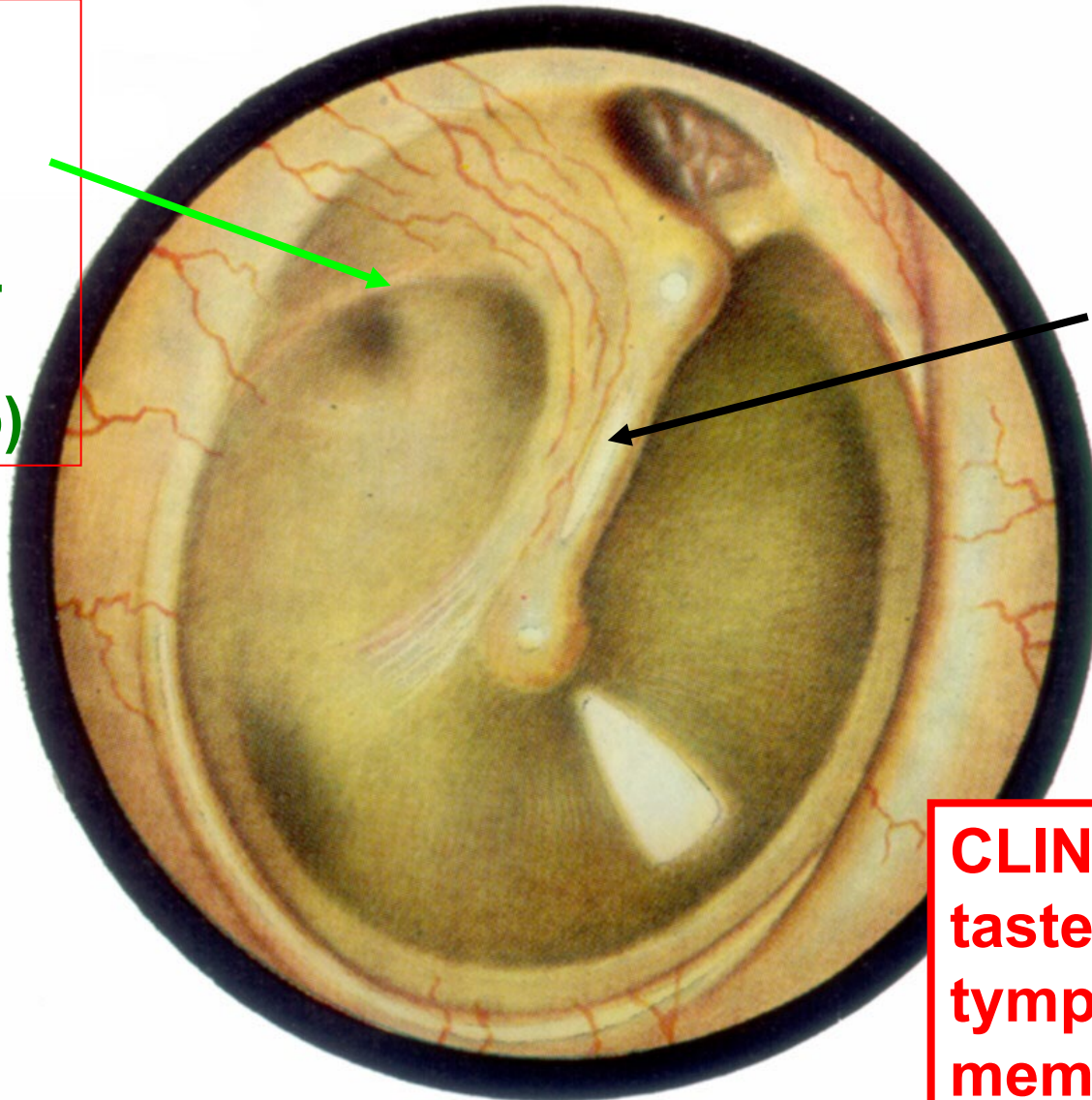
- Chorda Tympani has no function in middle ear
- Crosses through tympanic cavity
- Over handle of malleus

VIEW OF INNER SURFACE

FACIAL NERVE

# OTOSCOPE VIEW OF TYMPANIC MEMBRANE

**CHORDA  
TYMPANI:  
TASTE,  
VISCERAL  
MOTOR  
(parasymp)**



**MALLEUS –  
manubrium  
(handle)**

**CLINICAL: Lose  
taste if pierce  
tympanic  
membrane**